AVA 2024

This poster was presented at the AVA Annual Scientific Meeting.

7 Years of Clinical Outcomes for Axillary CVC Insertion Using Ultrasound by a Dedicated Vascular Access Team

Tyger Homan RRT, VA-BC

Purpose

To determine the efficacy and safety of adding the Axillary Vein insertion site to a dedicated vascular access team's approved procedures.

Background

Acute central line insertion has traditionally been preformed by physicians. Of non-physician providers inserting acute central lines, many of them are limited to one site: the internal jugular vein. This is likely due, in large part, to the fear of causing insertion related complications, most notably, pneumothorax.

Our dedicated team of respiratory therapists, that service a 405 bed combined campus, found itself constrained when trying to provide the most appropriate insertion site when limited to only the Internal Jugular Vein.

Despite an abundance of published evidence and guidelines that highlight the Subclavian/Axillary site as the preferred choice for infection prevention; many clinicians worry about the difficulty of access and about the risk of causing potentially life-threatening pneumothorax.

Subclavian vein access has been traditionally preformed using a landmark approach by physicians without ultrasound.

Ultrasound utilization as a whole, and by vascular access teams, has significantly reduced insertion related complications when accessing the Internal Jugular Vein and our team wanted to apply this skill set, with its many advantages, to the Axillary site as well.

At times, when called to place a CVAD, the team found patients with compromised skin, tracheostomies, C-spine limitations, and non compressible or inappropriate Internal Jugular Vein options, forcing patients to be referred to other providers or interventional radiology.

At it's worst, this limitation encouraged the team to place CVCs in suboptimal sites or veins simply because it was the only site they were "allowed" to use.

Through collaboration with our intensivists, we began inserting into the Axillary Vein using ultrasound in 2017.

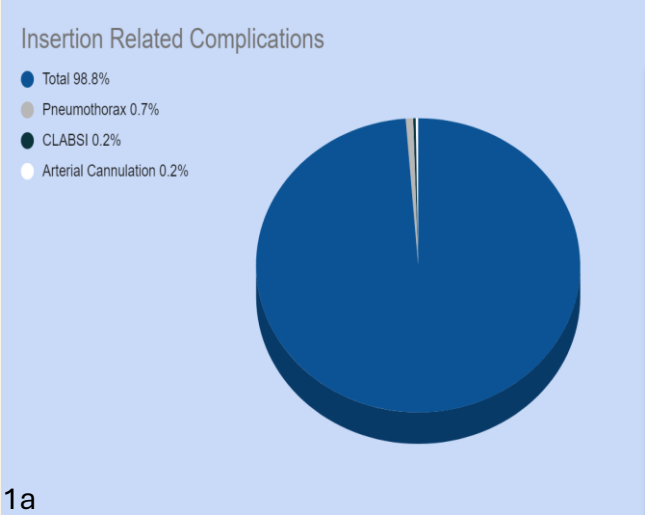

1a

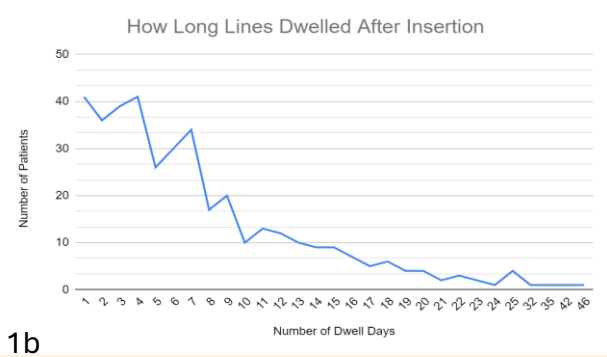

1b

Results

From 2017-2023 our team attempted 446 Axillary Vein insertions.

Complications were reviewed and defined as any need for IR or vascular surgery involvement or the identification of pneumothorax on post-insertion imaging.

During this timeframe, there were 3 pneumothoraces and one arterial cannulation. Using the above criteria, 4 complications were noted, making the total complication rate 0.9%.(See figure 1a)

Unsuccessful insertions, defined as an inability to insert the line or a tip location that required removal or replacement, had a 10% incidence. This presents an opportunity of better procedural identification of malposition and has been a valuable marker of improvement opportunity as well as demonstration of the potential benefit of implementing real time procedural tip confirmation technology as is traditionally used in PICC insertion.

During this period, there were 3.007 line days and only one incident of an infection meeting CLABSI criteria. See figure 1b for a breakdown of dwell times.

Conclusion

Our collaborative group of vascular access specialists, physicians, and administrators have concluded from the highlighted results, that the ultrasound guided approach to CVC insertion in the Axillary Vein is an acceptable and safe insertion site for our advanced practice team.

These successes provide evidence for vascular access teams, using ultrasound, to have access to an additional, invaluable site when providing the right line for the patient. An expert team should be leveraging their procedural ultrasound experience and skill set to include the use of the Axillary Vein for CVC insertion.