A Vascular Access Team's 7 Year Outcomes for Central Venous Insertions in an Alternative Femoral Site

Tyger Homan RRT, VA-BC

This poster was presented at the AVA Annual Scientific Meeting.

Purpose

To track outcomes and insertional complications of central venous catheters, including acute hemodialysis catheters, inserted into the Femoral Vein by a dedicated, advanced practice vascular access team using ultrasound.

Background

Prior to 2017, insertion sites for this team were limited to the upper extremities, Internal Jugular, and Axillary sites.
When clinical developments lead to the inability to successfully thread wires/catheters, or for patients with documented central venous occlusion, referral to IR or other providers became necessary. This often resulted in significant delays in patient care compared to the vascular access team's 24/7 service.
Patients with end stage renal failure requiring ongoing hemodialysis provided especially challenging cases as they often required multiple central venous access throughout the course of treatment and were at a greater risk of acquiring central stenosis.
The need for additional access sites for these patients led to our desire for expansion to the use of this site.
Traditionally this procedure was being preformed by physicians during emergent conditions, often without the use of ultrasound, and with questionable adherence to max sterile barrier precautions. This led to infection prevention related concerns and hesitation to allow the vascular access team to utilize this site.
The team was already habituated to following the abundance of clinical evidence showing improved outcomes of strictly adhering to central line insertion bundles as well as the use of ultrasound for all CVC insertion. The focus was to apply these complication reducing strategies, to this new site.
The concern for suboptimal site conditions in the groin was also addressed by following emerging published evidence of the benefits of mid-thigh central line insertion to reduce the risk of infection. A decision to access the vein as close to mid-thigh as anatomy and catheter length allowed, was instituted.
Through collaboration with intensivists and hospital administrators, we began inserting into the Femoral Vein in 2017.

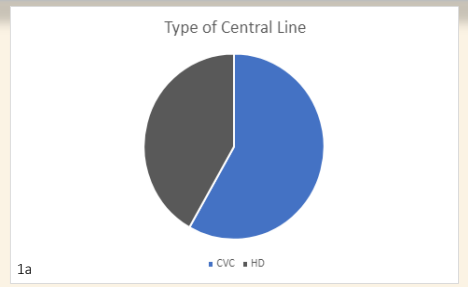

1a

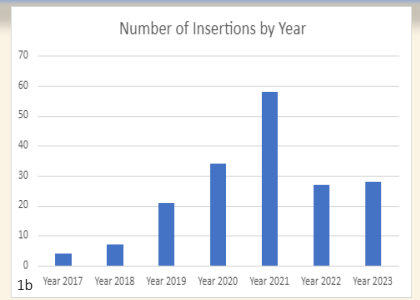

1b

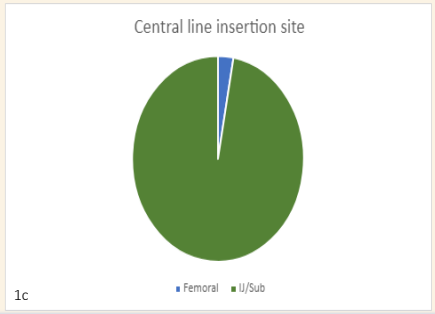

1c

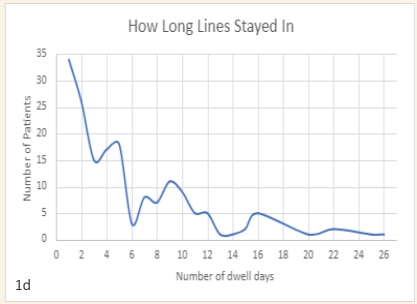

1d

Results

Between 2017-2023, our dedicated team of 9 respiratory therapists, providing a 24/7 vascular access service to a 405 bed combined campus, began utilizing this site. During this time there were a total of 172 central lines inserted into the Femoral Vein.
This conservative number is indicative of the judicious care that was used to rule out other, more optimal, insertion sites. (See figure1c)
58% of insertions were acute central lines compared to 42% of acute hemodialysis catheters. (See figure1a)
Complications were defined as DVT diagnosis, infections meeting CLABSI criteria, and any interventions that required the involvement of either a physician (vascular surgery consults) or interventional radiology. There were zero complications meeting those criteria.
Two catheters had to be replaced or over wired for optimal dialysis flows.
There were no documented adverse outcomes to bringing the insertion site away from the traditional insertion area of the inguinal fold.
All imaging records during the line's dwell were reviewed and no documented DVT findings were found.
In 975 line days, there was only one patient that met criteria for a reportable CLABSI.
Nineteen percent of catheters dwelled longer than 10 days. (see figure1d) The prolonged length of dwell likley represents the lack of other viable access options both in terms of general vascular access, and in hemodialysis.
Figure 1b shows a gradual increase in the team's comfort level of acclimating this new site.

Conclusions

This work demonstrates that an ultrasound guided approach of CVC insertion into the Femoral Vein by a specialized VAT team is an acceptable and safe insertion site. These outcomes are an attestation that vascular access teams using ultrasound can successfully augment their practice with this additional site with no advantage to referral of these patients to a non-VAT provider or IR team.