



## ABSTRACT/INTRODUCTION

Hypophosphatasia is a rare autosomal recessive disorder affecting the ALPL gene, which is involved in mineralization of bones and teeth. Given the importance of mineralization on proper tooth development, patients with hypophosphatasia present with numerous dental manifestations and require careful, coordinated care to maintain function and esthetics. This case report details a 9-year-old patient presenting to Children's Mercy Kansas City Dental Clinic with complex medical history including hypophosphatasia, hypophosphatemic rickets, and developmental delay. The case report will include the patient's clinical and radiographic presentation and will detail the patient's treatment history. The presentation will also review the relevant scientific literature regarding hypophosphatasia and the clinical expectations for overall care.

## CASE REPORT

The patient first presented to the Children's Mercy Outpatient Pediatric Dental Clinic at the age of 2 for a comprehensive oral examination with chief concern of loose lower front teeth. Medical history was obtained and was significant for hypophosphatasia, hypophosphatemic rickets, developmental delay, and nutrition via G-tube. Oral exam at that time revealed generalized calculus and #O and #P with class 3 mobility. The patient was scheduled for dental rehabilitation under general anesthesia due to her complex medical history. Radiographs (Figures 1,2, and 3 below) from dental rehab in 2016 shown below exhibit severely affected primary dentition with poor root formation. Teeth #O and #P were removed at this time and a full mouth debridement was performed.

The patient was seen again for dental rehab under general anesthesia in 2019 where teeth #A,I, and J were extracted due to poor root and crown formation. The patient returned to the outpatient clinic for evaluation in 2021 and exam revealed generalized calculus buildup and generalized poor dentition. The patient was seen for dental rehabilitation under general anesthesia in 2022. Radiographs (Figures 4,5, and 6 below) reveal severe breakdown and poor root/crown formation of the permanent dentition. The decision was made to extract tooth #B,8, and 30.

Long-term prognosis for the patient's dentition is poor as both primary and permanent dentition are affected by her medical conditions. Future care will focus on maintaining restorable teeth and removal of non-restorable and mobile teeth. If the patient is able to progress to nutrition via solid foods, restoration of function using removable prostheses may be considered if tolerated by the patient.

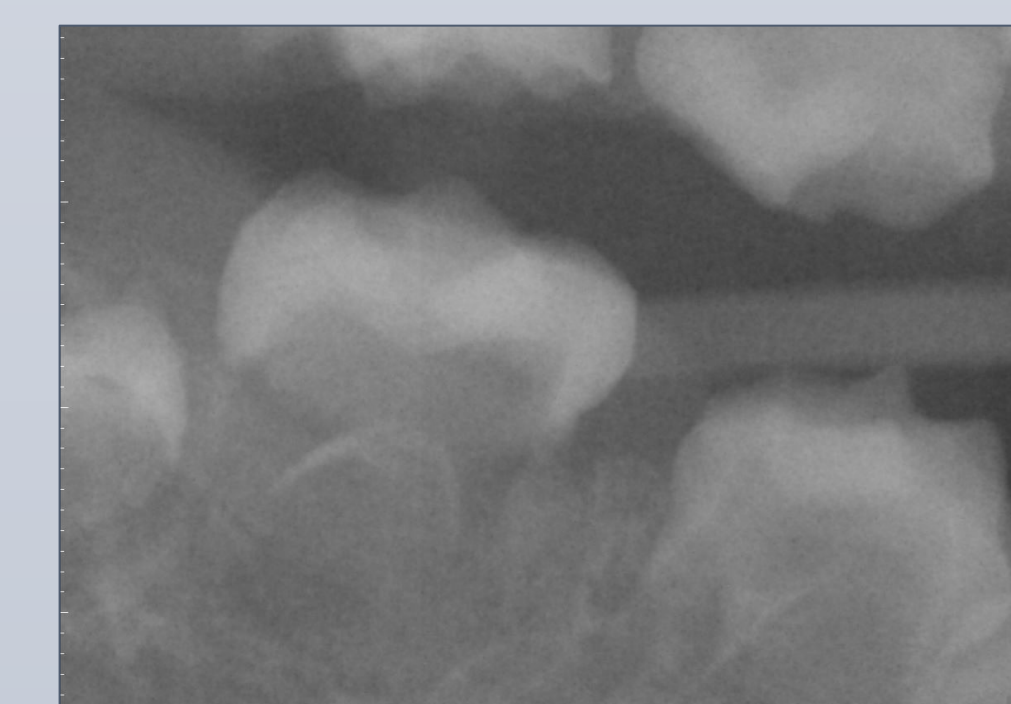


Figure 1. Right Bitewing 12/21/2016

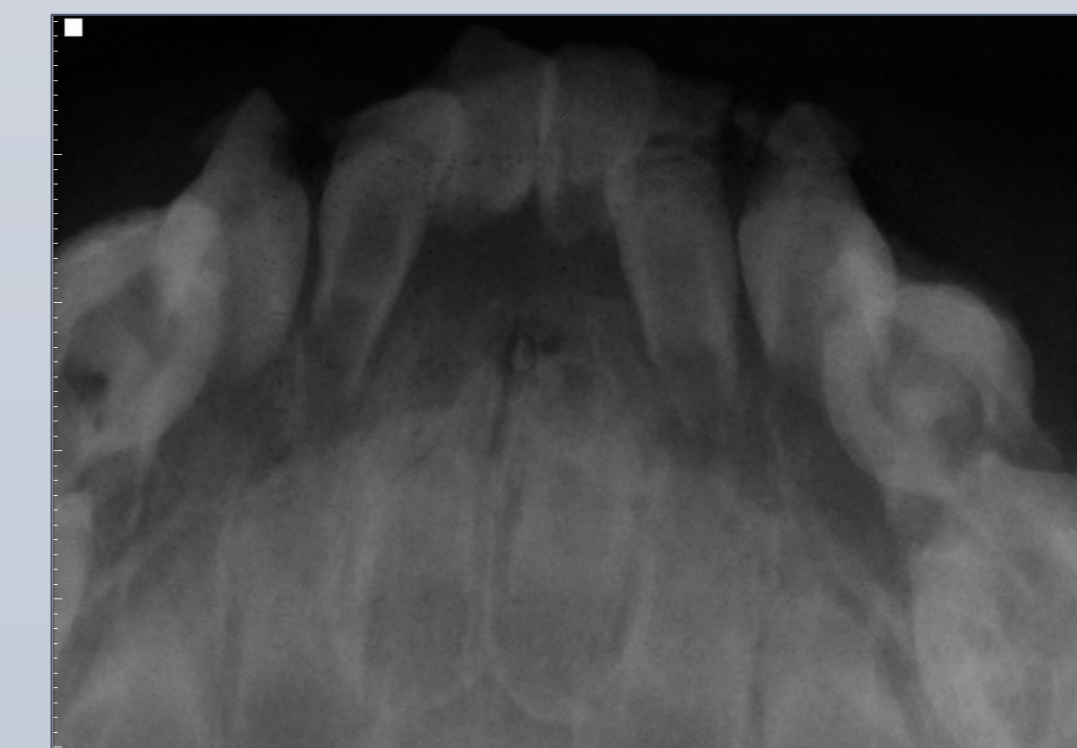

Figure 2. Mandibular Periapical 12/21/2016

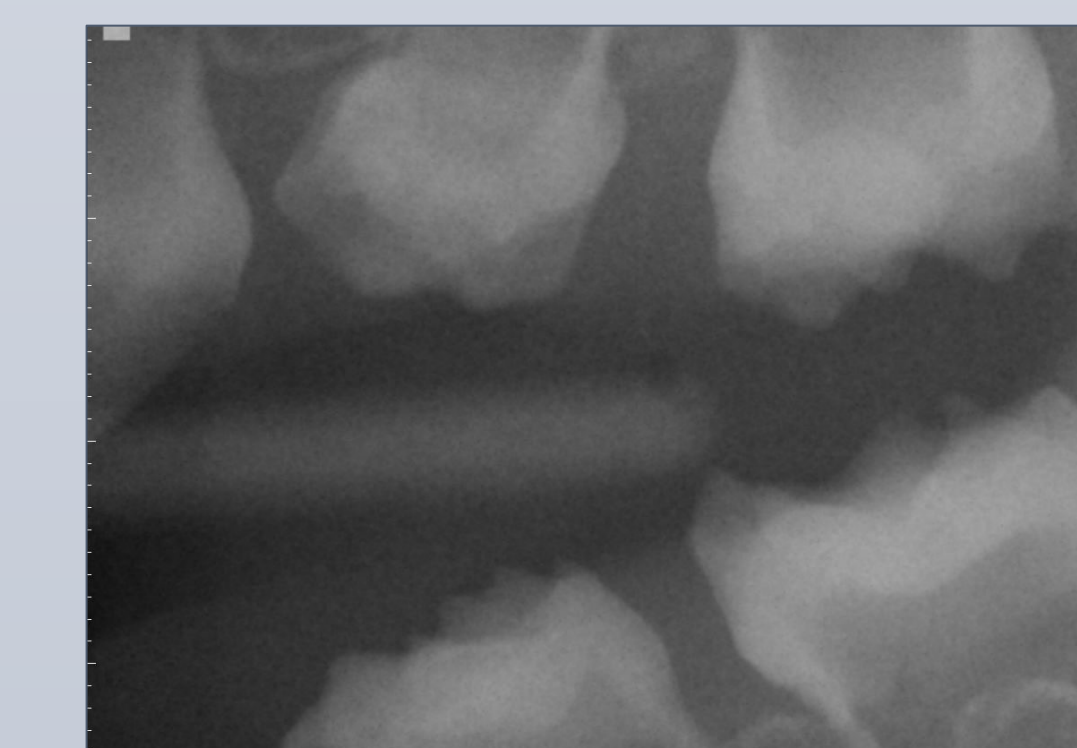


Figure 3. Left Bitewing 12/21/2016

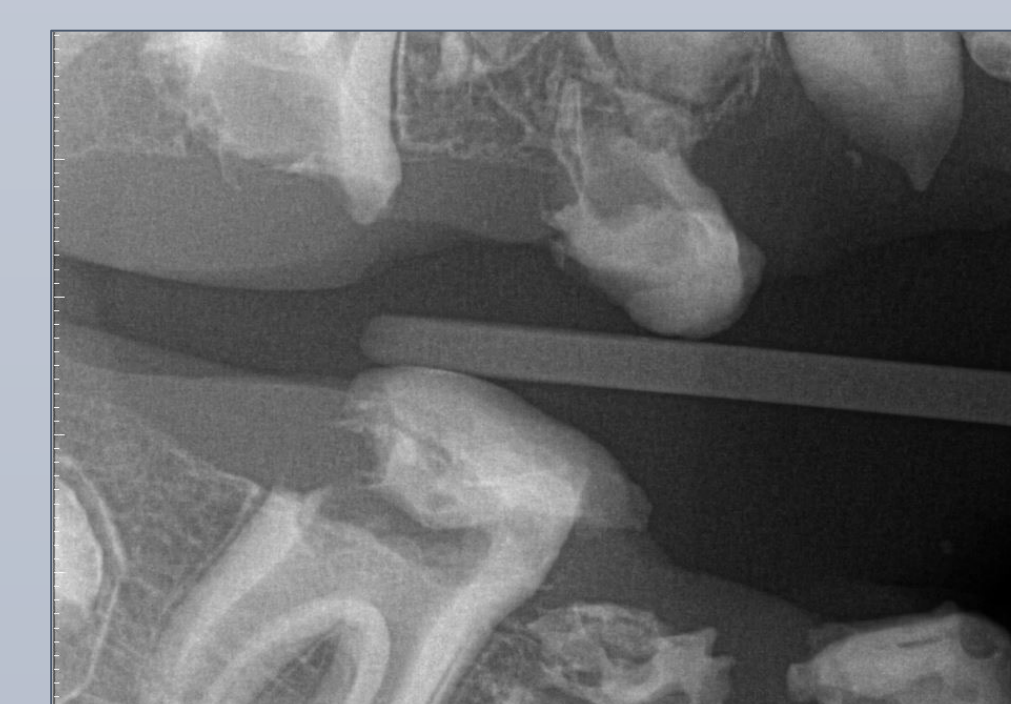

Figure 4. Right Bitewing 4/27/2022

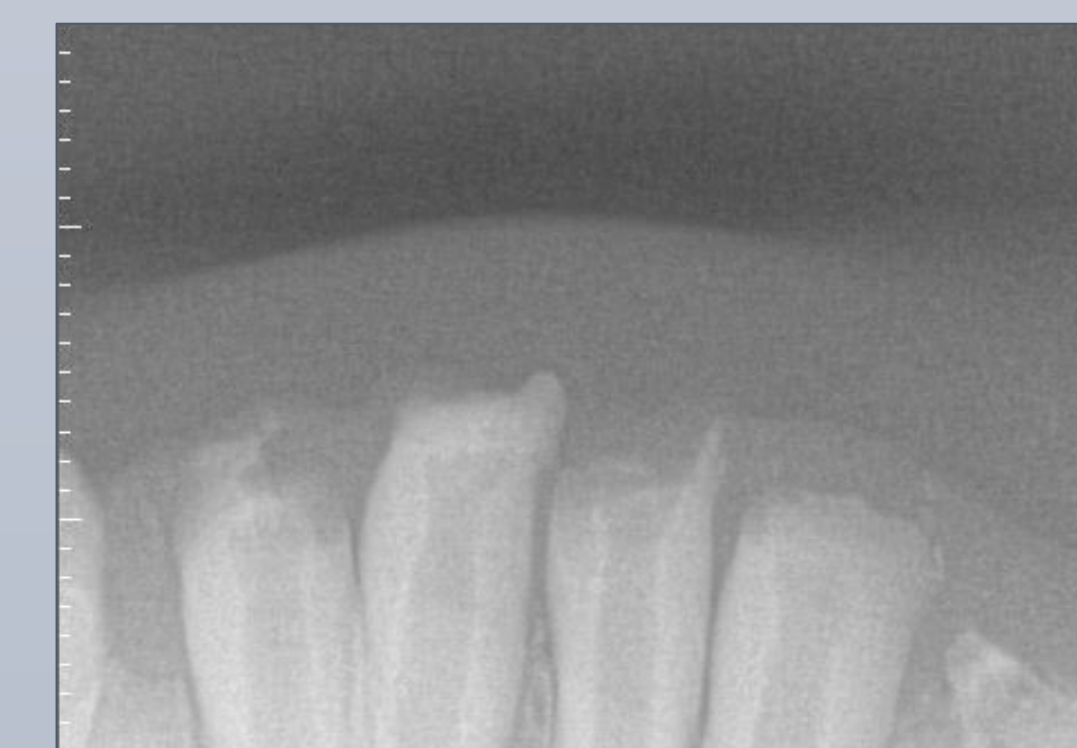


Figure 5. Mandibular Periapical 4/27/2022

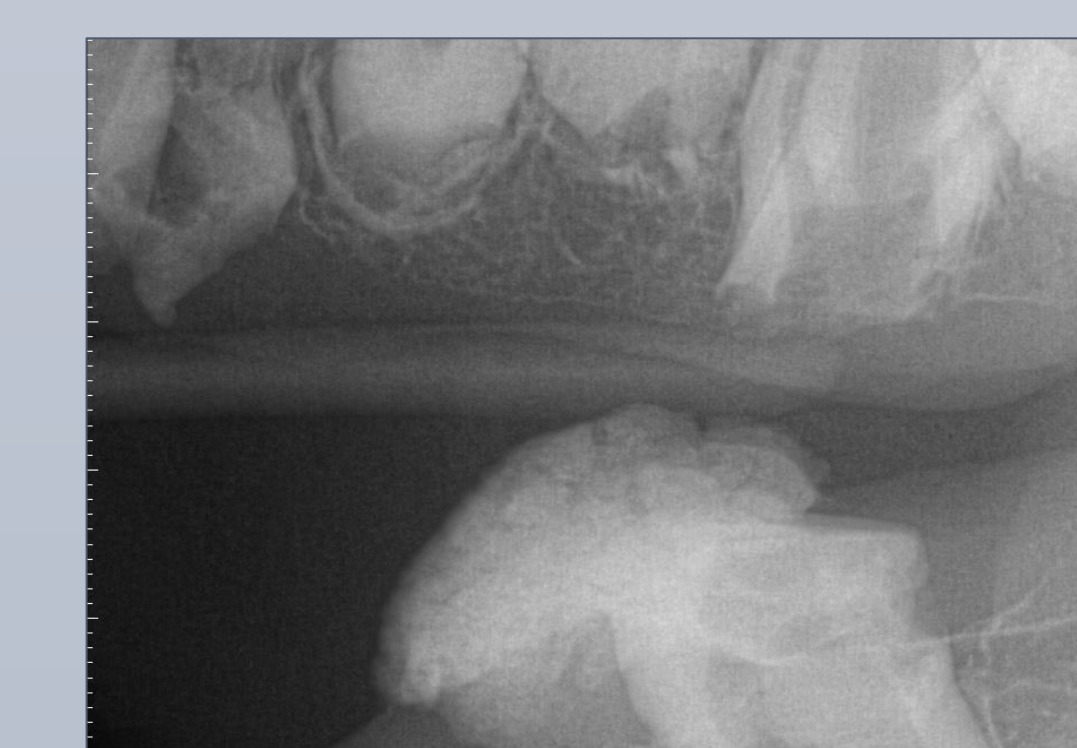

Figure 6. Left Bitewing 4/27/2022

## DISCUSSION/CONCLUSION

Hypophosphatasia is a rare, autosomal recessive inherited disorder that results in inactivating mutations in the ALPL gene. As a result, alkaline phosphatase enzyme activity is decreased, causing impairment in bone mineralization. Hypophosphatasia is classified into 6 different types based on the period of diagnosis. Generally, the earlier hypophosphatasia is diagnosed, the more severe symptoms the patient will experience. Symptoms include severe bone hypomineralization, failure to thrive, short stature, and early exfoliation of primary teeth. Diagnosis of hypophosphatasia includes biochemical testing revealing decreased serum alkaline phosphatase and urinalysis showing elevated phosphoethanolamine (PEA). Treatment of hypophosphatasia includes enzyme replacement therapy.<sup>1</sup>

A hallmark feature of the dental manifestations of hypophosphatasia is early exfoliation of primary teeth with a lack of root resorption. Up to 75% of children with skeletal symptoms experience early loss of primary teeth. Thus, it is imperative to accurately identify patients with early loss of primary teeth in the absence of caries or trauma and make appropriate referrals for testing.<sup>2</sup>

Oftentimes, early exfoliation of primary teeth cannot be avoided in patients with hypophosphatasia due to abnormal cementum formation. Management of patients with early loss of primary teeth can include prosthetics if needed to restore function and can be tolerated by the patient; however, compliance with wearing removable prostheses can be low in pediatric populations.

## REFERENCES

1. Spodzieja, K.; Olczak-Kowalczyk, D. Premature Loss of Deciduous Teeth as a Symptom of Systemic Disease: A Narrative Literature Review. *Int. J. Environ. Res. Public Health* 2022, 19, 3386. <https://doi.org/10.3390/ijerph19063386>.
2. Okawa R, Nakano K. Dental manifestation and management of hypophosphatasia. *Jpn Dent Sci Rev.* 2022 Nov;58:208-216. doi: 10.1016/j.jdsr.2022.06.002. Epub 2022 Jul 2. PMID: 35814738; PMCID: PMC9260292.