

Contrast dose optimization in Transcatheter Aortic Valve Implantation (TAVI) planning Computed Tomography Angiography (CTA)

Sajeev Sridhar, MD¹, Riley Mager², Pamela Mager, BA¹, Pankaj Patel, PhD¹, Jett Brady, MD^{1,3}, John Nance, MD^{1,3}, Nakul Gupta, MD^{1,3}

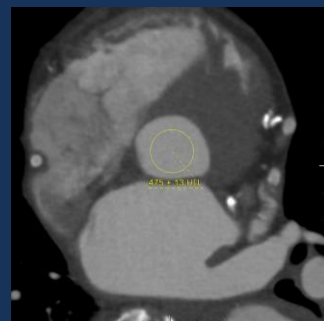
¹Department of Radiology, Houston Methodist Hospital, ²Texas A&M University, ³Houston Radiology Associated

BACKGROUND & PURPOSE

- TAVI is widely accepted in the treatment of AS.^{1,2}
- CTA is the gold standard for pre-surgical planning.³
- Iodinated contrast material (CM) carries risk of contrast induced nephropathy (CIN).⁴ Excessive application may not be required (Figure 1).
- CT Technique has a major impact on image quality and protocol optimization is required.⁵
- We assessed the effect of an optimized CM regimen on image quality improvement in Pre-TAVI planning CTA studies after employing a protocol with more gradation in larger patients compared to the old protocol.

FIGURE 1

89 yo M
BMI: 23.0
CM given 75cc
HU: 475

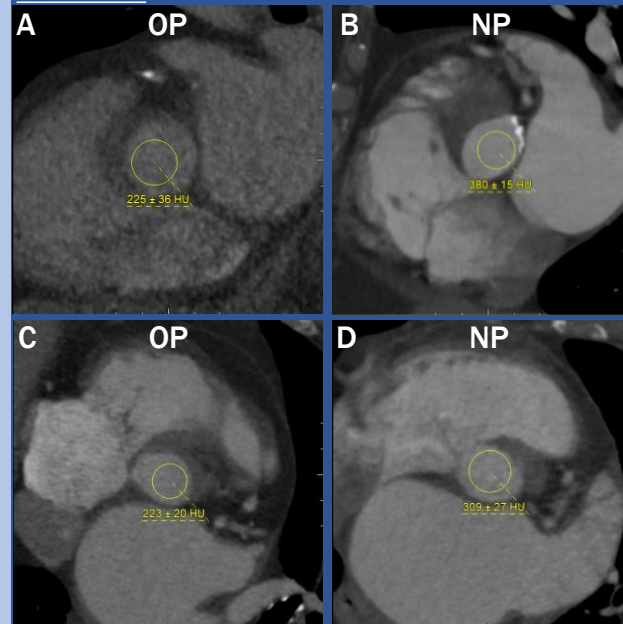


Example of excessive CM administration. Seen in both protocols in group sizes S/M and L.

RESULTS

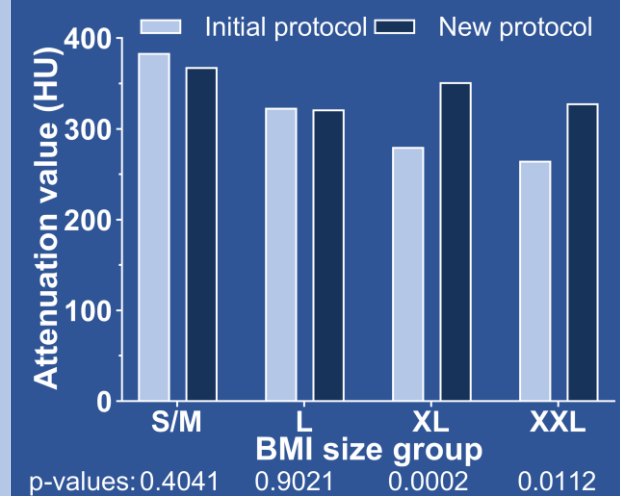
- Figure 3 shows the quantitative differences between initial and new protocols.
- Percentage of satisfactory scans in the XL group increased from 69% to 95% (p=0.0364), and from 40% to 100% (p=0.0019) in the XXL group.

FIGURE 2



A. 62 yo M w/ BMI 36.6 given 75cc CM
B. 75 yo F w/ BMI 36.1 given 100cc CM
C. 74 yo F w/ BMI 41.0 given 100cc CM
D. 74 yo F w/ BMI of 46.6 given 160cc CM

FIGURE 3



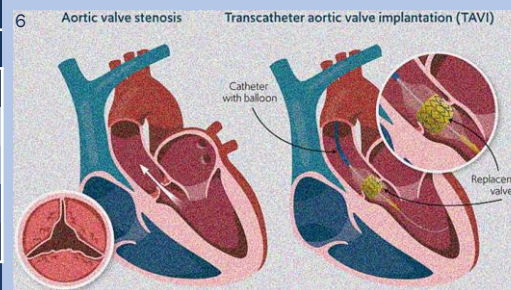
REFERENCES

- Leon MB, Smith CR, Mack M, et al. Transcatheter aortic-valve implantation for aortic stenosis in patients who cannot undergo surgery. *N Engl J Med.* 2010;363(17):1597-1607. doi:10.1056/NEJMoa1008232
- Annoni AD, Andreini D, Pontone G, et al. CT angiography prior to TAVI procedure using third-generation scanner with wide volume coverage: feasibility, renal safety and diagnostic accuracy for coronary tree. *Br J Radiol.* 2018;91(1090):20180196. doi:10.1259/bjr.20180196
- Achenbach S, Delgado V, Hausleiter J, Schoenhagen P, Min JK, Leipsic JA. SCCT expert consensus document on computed tomography imaging before transcatheter aortic valve implantation (TAVI)/transcatheter aortic valve replacement (TAVR). *J Cardiovasc Comput Tomogr.* 2012;6(6):366-380. doi:10.1016/j.jcct.2012.11.002
- Rundback JH, Nahl D, Yoo V. Contrast-induced nephropathy. *J Vasc Surg.* 2011;54(2):575-579. doi:10.1016/j.jvs.2011.04.047
- Kok M, Turek J, Muhl C, et al. Low contrast media volume in pre-TAVI CT examinations. *Eur Radiol.* 2016;26(8):2426-2435. doi:10.1007/s00330-015-4080-x
- What is TAVI? RB&HH Specialist Care. Web Site. <https://www.rbhh-specialistcare.co.uk/news/what-is-tavi> Published May 31, 2023. Accessed March 17, 2024

TABLE 1

BMI		Initial protocol		New protocol	
Range (kg/m ²)	Group	CM dose (cc)	n	CM dose (cc)	n
17.5-28.4	S/M	50	14	50	15
28.5-33.4	L	75	15	75	16
33.5-39.4	XL	75	16	100	20
>39.4	XXL	100	15	125-160*	9

*At the radiologist's discretion, based on the desired flow rate



METHODS/MATERIALS

- Retrospective assessment of 120 age and sex-matched patients who had a Pre-TAVI CTA between 2020-23.
- n=60 prior to CM protocol change and n=60 after (Table 1).
- kVp was 100 kVp for S/M patients and 120 kVp for others.
- Scans were obtained on a 256-detector CT (Revolution CT, GE Healthcare, Waukesha) with automated tube current modulation. Omnipaque™ 350 was used for IV CM.
- Attenuation (HU) at the aortic root was measured, with ≥ 250 HU considered satisfactory. Student's T-test was used to compare pre- & post-intervention attenuation per size group.
- Independent samples T-test was used to compare scan satisfaction by binarizing outcomes as 1=satisfactory and 0=unsatisfactory.

CONCLUSION

Adoption of an optimized size-based CM administration protocol yielded significant improvement in image quality in larger patients as seen in Figure 2.