

A-Z syndromes

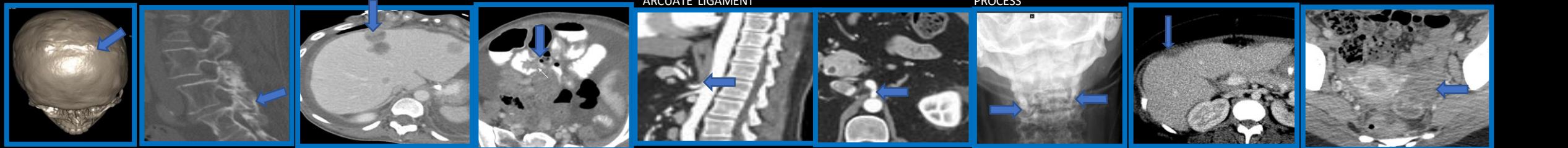
Vidhyulatha Sanata¹, Eduardo Matta, Mahesh Chaudhary, Steven S Chua

Radiology plays a crucial role in the diagnosis and management of many clinical syndromes, which are collections of symptoms and signs that often reflect an underlying disease process.

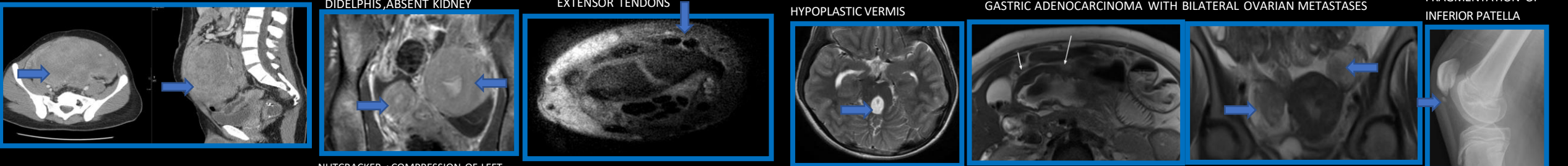
Imaging is an essential component of diagnosis and management of many clinical syndromes.

APERT ,BAASTRUP ,CARCINOID ,DUNBAR,,EAGLES,FITZ-HUGH-CURTIS ,GARDNER,HERLYN WERNER WUNDERLICH,INTERSECTION,,JOUBERT,KRUKENBER, LARSEN JOHANSSON ,MAFFUCCI, NUTCRACKER ,OS TRIGONUM, PARKINSONS,,DEQUERVAINS,RADIAL RAY ,SUPERIOR MESENTERIC ARTERY,TREACHER COLLINS, ULNAR STYLOID IMPACTION,VACTERL, WAGR, FRAGILE X ,YELLOW NAIL, ,ZELLWEGER SYNDROMES.

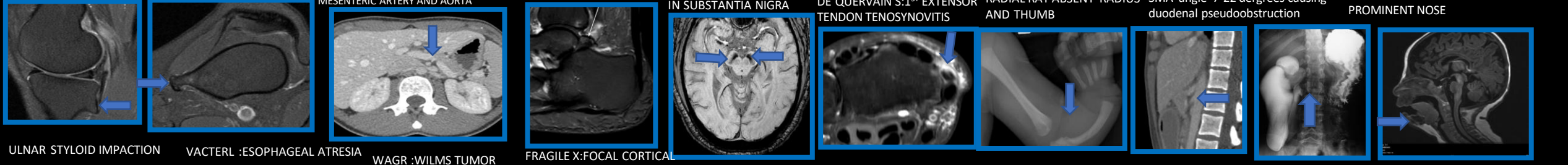
APERT:CRANIOSYNOSTOSES BAASTRUP'S: KISSING SPINES CARCINOID : HEPATIC METASTASES, ILEAL MASS DUNBAR :CELIAC ARTERY COMPRESSION BY MEDIAN ARCULATE LIGAMENT EAGLES :ELONGATED STYLOID FITZ-HUGH-CUTIS: RIGHT SUBCAPSULAR COLLECTION,LEFT OVARIAN ABSCESS



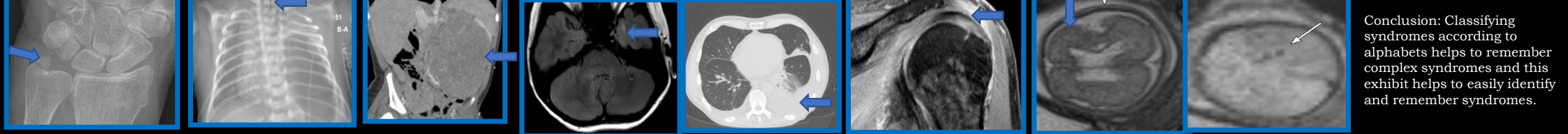
GARDNER: DESMOID TUMOR HERLYN WERNER WUNDERLICH:UTERINE DIDELPHIS,ABSENT KIDNEY INTERSECTION: FLUID BETWEEN EXTENSOR TENDONS JOUBERT : ELONGATED SUPERIOR CEREBELLAR PEDUNCLES, HYPOPLASTIC VERMIS KRUKENBERG SYNDROME GASTRIC ADENOCARCINOMA WITH BILATERAL OVARIAN METASTASES LARSEN-JOHANSSON FRAGMENTATION OF INFERIOR PATELLA



MAFFUCCI: MULTIPLE ENCHONDROMAS NUTCRACKER : COMPRESSION OF LEFT RENAL VEIN BETWEEN SUPERIOR MESENTERIC ARTERY AND AORTA OS TRIGONUM SYNDROME PARKINSONS:IRON DEPOSITION IN SUBSTANTIA NIGRA DE QUERVAIN'S:1ST EXTENSOR TENDON TENOSYNOVITIS RADIAL RAY ABSENT RADIUS AND THUMB SUPERIOR MESENTERIC ARTERY SMA angle 7-22 dergrees causing duodenal pseudoobstruction TREACHER COLLINS RETROGNATHIA PROMINENT NOSE



ULNAR STYLOID IMPACTION VACTERL :ESOPHAGEAL ATRESIA TRACHEOESOPHGEAL FISTULA WAGR :WILMS TUMOR FRAGILE X:FOCAL CORTICAL DYSPLASIA LEFT TEMPORAL LOBE YELLOW NAIL :CHRONIC LUNG DISEASE RHEUMATOID ARTHRITIS ZELLWEGER: POLYMICROGYRIA, PARENCHYMAL CYSTS



Conclusion: Classifying syndromes according to alphabets helps to remember complex syndromes and this exhibit helps to easily identify and remember syndromes.