

# Application of Intact Fish Skin Grafts\* (FSG) on an Inguinal Ulceration in a Quadriplegic Patient

Luis J. Navazo, MD

Mobile Doctor Medical Clinic, Oceanside, CA

## INTRODUCTION

Fish skin graft (FSG) is a novel product derived from Atlantic cod fish and has been proven to augment acute and chronic wound healing<sup>3,4</sup>. Therefore, the purpose of this case is to evaluate FSG in a quadriplegic patient with a complication of a nonhealing ulceration that had failed conservative treatment. Patient developed wound subsequent to catheterization procedure using femoral artery on right side.

## METHODS

Patient is a 69-year-old quadriplegic male with cerebral palsy who presented with a four-month-old nonhealing right inguinal ulcer that had failed conservative wound care. Initial wound size measured at 2.0 cm x 1.5 cm x 0.3 cm. The patient underwent surgical debridement and application of intact fish skin graft (MariGen Micro 3cm x 3.5cm). Patient was seen nine days later, at which point wound size measured 1.5 cm x 1.0 cm x 0.2 cm, and underwent a second application of intact FSG. Patient was seen for final visit eighteen days later, at which point wound size measured 2 mm x 4 mm. Third treatment with intact FSG at this visit led to subsequent wound closure the following week.

## REFERENCES

1. Mervis, J. S., & Phillips, T. J. (2019). Pressure ulcers: Pathophysiology, epidemiology, risk factors, and presentation. *Journal of the American Academy of Dermatology*, 81(4), 881–890. <https://doi.org/10.1016/j.jaad.2018.12.069>
2. Lindgren, Unosson, M., Fredrikson, M., & Ek, A.-C. (2004). Immobility - a major risk factor for development of pressure ulcers among adult hospitalized patients: a prospective study. *Scandinavian Journal of Caring Sciences*, 18(1), 57–64. <https://doi.org/10.1046/j.0283-9318.2003.00250.x>
3. Kirsner, R. S., Maripolis, D. J., Balderson, B. T., Petrusdottir, K., Davidson, O. B., Weir, D., & Lantis, J. C., 2nd (2020). Fish skin grafts compared to human amnion/chorion membrane allografts: A double-blind, prospective, randomized clinical trial of acute wound healing, wound repair and regeneration: official publication of the Wound Healing Society [and] the European Tissue Repair Society, 28(1), 75–80. <https://doi.org/10.1111/wrr.12761>
4. Lullove, E. J., Liden, B., Winters, C., McEneaney, P., Raphael, A., & JG, L. I. (2021). A Multicenter, Blinded, Randomized Controlled Clinical Trial Evaluating the Effect of Omega-3-Rich Fish Skin in the Treatment of Chronic, Nonresponsive Diabetic Foot Ulcers. *Wounds: A Compendium of Clinical Research and Practice*.

## RESULTS

Wound was evaluated regularly after each application of intact FSG. Within five weeks and three applications of intact FSG, the wound had achieved complete closure. (Initial wound size: 2.0 cm x 1.5 cm x 0.3 cm. Week 4 Follow-up: 2 mm x 4 mm.)

## DISCUSSION

This case illustrates clinical efficacy in treating nonhealing ulcerations using FSG in a male quadriplegic. The product proved a safe and effective option for wound closure at the patient's residence. The FSG was easily applied each time at the patient's home, required minimal maintenance, and augmented healing after conservative wound care had failed. More extensive prospective studies should investigate FSG efficacy in treating these types of ulcerations in patients with neurological diseases.

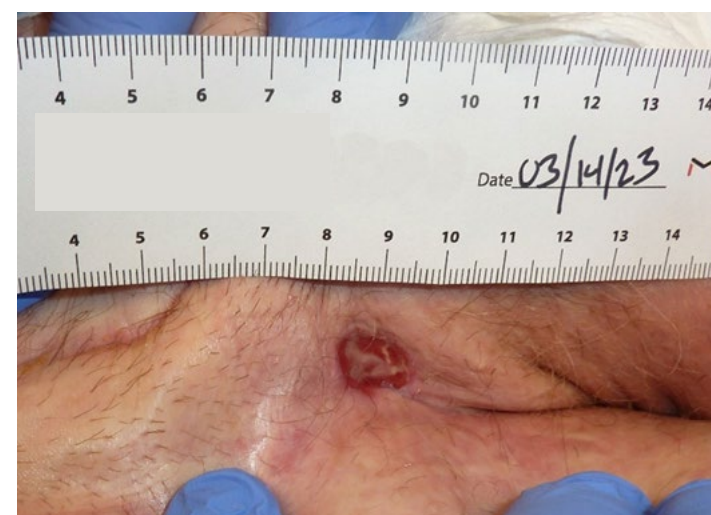
## CASE: 69-YEAR-OLD MALE NONHEALING INGUINAL ULCERATION

Patient History: 69-year-old quadriplegic male with PMH of cerebral palsy and quadriplegia

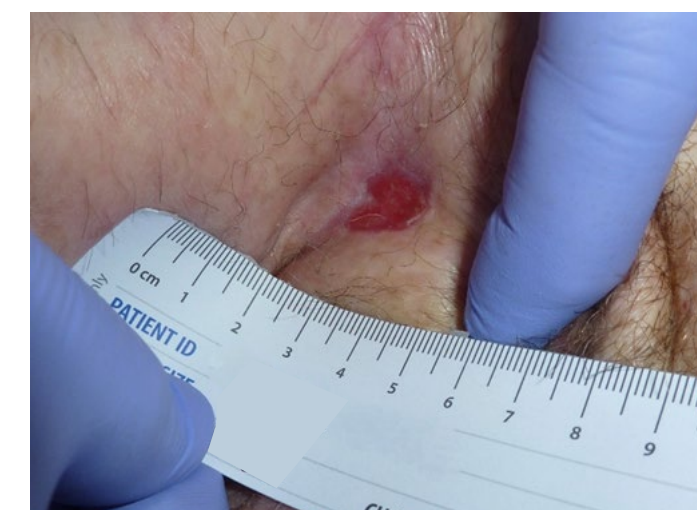Wound History: Patient presented with a four-month-old nonhealing right inguinal ulceration that had failed conservative wound care

Kerecis Applications: Three applications of intact fish skin graft (MariGen Micro 3cm x 3.5cm)

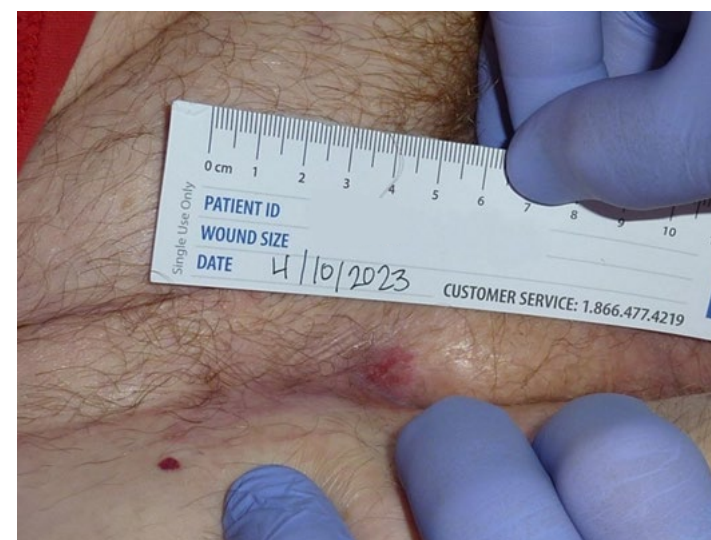Patient Outcomes: Wound achieved complete closure one week after third application of intact fish skin graft



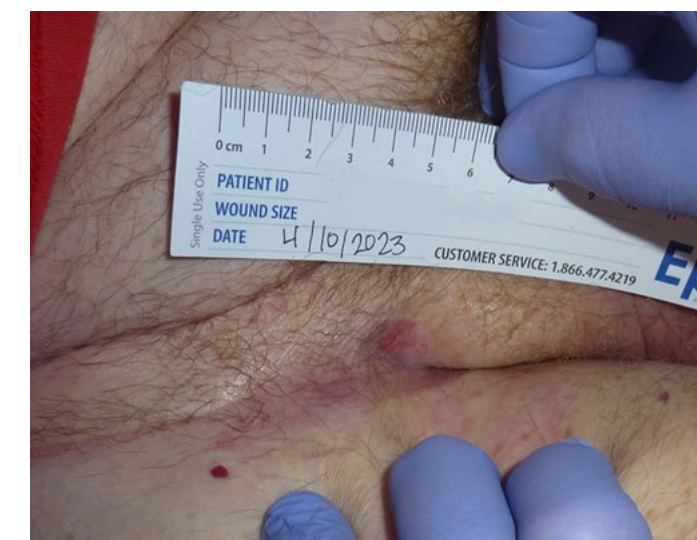Initial presentation (3/14/2023)  
Wound size: 2.0 cm x 1.5 cm x 0.3 cm



Week 1 Follow up (3/23/2023)  
Wound size: 1.5 cm x 1.0 cm x 0.2 cm



Week 4 Follow up (4/10/2023)  
Wound size: 2 mm x 4 mm



Final Healing Outcome (4/10/2023)