Going Mobile - Patient Engagement & Satisfaction Improvement

with Innovative Portable Technology in the patient's Home

HealPrecisely™ ADVANCED WOUND CARE

Authors: *Ali Saberi, MD | Christina Asher, APRN | Amber Gephart, APRN, FNP-C | Patrick Reid, APRN | Yisel Ruiz, APRN | Lori Back, APRN | Evan Brewer, APRN | Audrey K Moyer-Harris, BSN, RN, MBA, CWS*

Introduction

Complex chronic wounds mixed with multiple comorbidities, typically evoke pain and anxiety which make treatment a challenge. This case series examines adjunct modalities in our Advanced Wound Care Mobile Practice (AWCMP) allowing providers to utilize technologies improving patient care and improving healing rates in the patient's home setting. The novel vibrating wound hygiene system is a mechanical debridement tool (VMDT) which uses low sonic level frequency vibrations to scrub and debride wounds. This tool is battery powered with a reusable hand piece that can be wiped clean. This novel hand-held tool uses vibrational technology in combination with debridement and scrubbing heads and has been used to cleanse wounds, safely disrupt biofilm and necrotic tissue. The purpose of the study was to evaluate this new technology, determining effectiveness for those patients who cannot tolerate traditional debridement methods, or the provider felt it was medically necessary to enhance management of wounds/ ulcers bioburden/necrotic tissue.

Pt #1 - 34 year old male, had developed in 2020 heart failure, experienced a cardiac arrest and suffered a severe anoxic brain injury. Pressure injuries started in September 2023. Hx of RBKA due Pressure Injury resulting into osteomyelitis. He currently has multiple pressures (buttock, coccyx, gluteal fold, back and left foot 5th digit metatarsal). VMDT was used in combination of standard of care (nutrition, offloading, infection management etc), including selective / surgical debridement, and NPWT

Methods

Several patients with different types of chronic wounds managed by our AWCMP in the home setting were evaluated wound bed status varied from clean to heavily contaminated. Wounds were assessed and cleaned/ debrided according to standard protocol. The VMDT replaced/augmented standard methods (curette/scalpel). Images were captured before/after debridement, patients were asked about overall satisfaction and pain. A random sampling of ie. venous, arterial, diabetic ulcers and pressure. Data was collected prospectively, and patients were followed to the end of the trial. Weekly progress was evaluated to include wound measurements, fluorescence imaging, pain scale, and patient satisfaction survey.

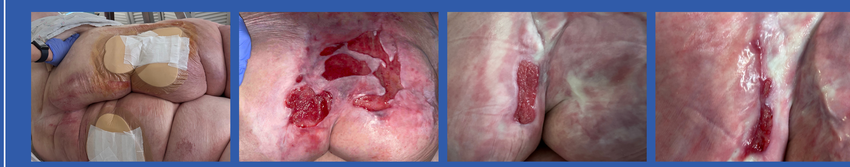



Pt #2 - 61 year old female with PMH of CHF, obesity and chronic wounds (Pressure Injuries/MASD, friction / shear) due to challenges with transferring and caregiver support. Initiated standard of care, lots of patient education and engagement to plan of care.

Pt #3 - 75 year old female who resides in an ALF, she fell a few months back and injured her LLE, initiated standard wound care including debridement, and utilization of the VMDT device.

DATE	WEEKS IN TREATMENT	LENGTH (CM)	WIDTH (CM)	DEPTH (CM)	AREA (SQ CM) BASED ON L*W	VOLUME (CM^3) BASED ON $AREA^2D$
3/15/2024	1	4.4	2.4	0,1	10.56	1.056
3/21/2024	2	2.1 (52.3%)	0.9 (62.5%)	0,1	1.89 (82%)	0.189 (81.9%)
4/4/2024	3	1.3 (70.5%)	0.7 (70.8%)	0,1	0.91 (91%)	0.091 (91.4%)
4/11/2024	4	1 (77.3%)	0.6 (75%)	0,1	0.6 (94%)	0.06 (94.3%)

Results

Clinically, the VMDT achieved a similar result in cleansing/ debridement as traditional methods (scalpel and sharp curettes). However, patient satisfaction/ compliance increased along with the pain reduction through vibratory analgesia. Which in turn decreased patient anxiety, depression, and time to debride compared to standard method of debridement. VMDT improved the patients' engagement with their plan of care.

Discussion

One of the top priorities of wound management is adequate debridement and granulation tissue. Having access to advanced technology in the patient's home at bedside improves overall satisfaction and time to resolution. The VMDT stimulates microbleeding in the wound bed that jumpstarts healing by cleaning and debriding chronic and contaminated wounds.

Debriding a wound properly and effectively before the final epitheliazation stage is crucial for a proper healing outcome. VMDT has been seen to be less painful for the patient, reduces bioburden, and appears to be a more effective alternative to standard debridement methods. Having VMDT available for our AWCMP providers in the mobile setting is one more added tool in their toolbox to manage patient's painful complex wounds.

References

- Lammers RL and Smith ZE, Principles of Wound Management, Ch. 34 Clinical Gate Emergency Medicine, 2015.
- Manna B, Morrison CA. Wound Debridement. [Updated 2020 Feb 14]. In: StatPearls [Internet]. Treasure Island (FL): StatPearls Publishing; 2020 Jan-.
- Gebreyohannes et al, Challenges of intervention, treatment, and antibiotic resistance of biofilm-forming mi croorganisms, Heliyon 5 (2019).
- Stevenson P and Schultz G, The Emerging Science of Biofilm 2019: International Consensus Includes Biofilm Treatment as New Standard of Care, OWM, 2019, Vol 65 (7), July 2019.
- World Union of Wound Healing Societies (WUWHS), Florence Congress, Position Document. Management of Biofilm. Wounds International 2016
- Murphy C, Atkin L, Swanson T, Tachi M, Tan YK, Vega de Ceniga M, Weir D, Wolcott R. International consen sus document. Defying hard-to-heal wounds with an early antibiofilm intervention strategy: wound hygiene. J Wound 6) Care 2020; 29(Suppl 3b): S1–28.
- Wolcott RD et al, Biofilm maturity studies indicate sharp debridement opens a time-dependent therapeutic window, JWC Vol 19 (8), 2010: 320-328.
- Schultz, G., Bjarnsholt, T., James, G.A., Leaper, D.J., McBain, A.J., Malone, M., Stoodley, P., Swanson, T., Tachi, M., Wolcott, R.D. and (2017), Consensus guidelines for the identification and treatment of biofilms in chronic nonhealing wounds. Wound Rep and Reg, 2017 (25): 744–757.
- Murphy C, Atkin L, Vega de Ceniga, weir D, Swanson T. International Consensus document. Embedding Wound hygiene into a proactive; 31: S1-S24

XSONX® HEAL WOUNDS BETTER

Scan to learn more about **HealPrecisely™**

5880 49th Street North, Suite N-201 St. Petersburg, FL 33709

www.healprecisely.com