

A Case Series: Lyophilized Human Amnion Chorion Membrane (LHACM*) in the Treatment of Diabetic Foot Ulcers

Megan Olmann DPM, FACFAS¹; Carol A Devlin PhD, RN, MSN, RNFA, CNOR²

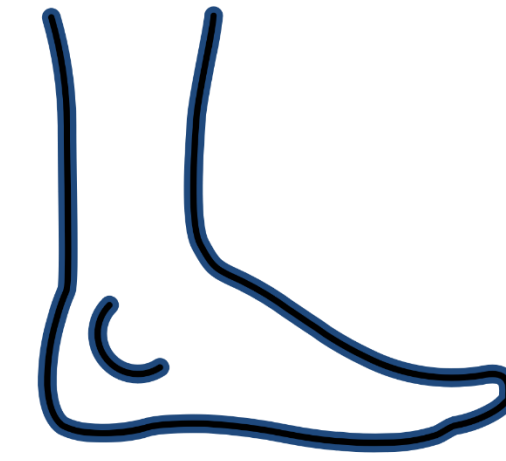
¹University Hospitals Harrington Heart & Vascular Institute, Cleveland, OH, ²MIMEDX Group, Inc., Marietta, GA

Increasing Diabetic Chronic Wound Rates¹:



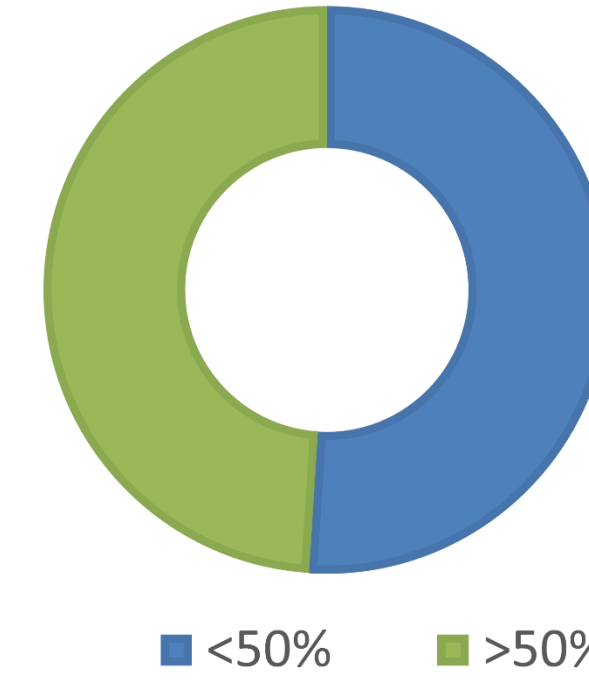
14.5% (2014) Versus 16.3% (2019)

Chronic Wounds i.e., DFU²⁻⁸:

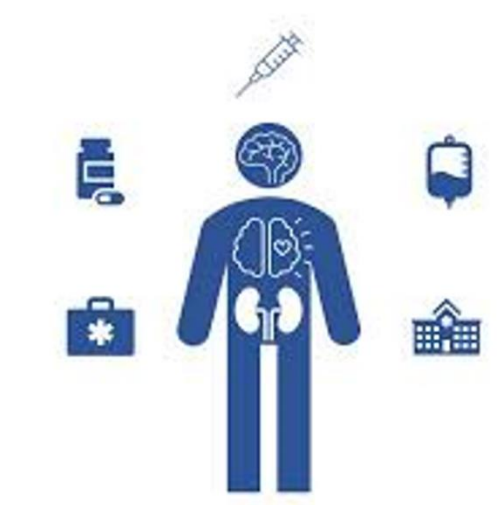


Advanced therapies, i.e., DHACM, are Indicated


Chronic Wound Definition³⁻⁸: Despite SOC, <50% Wound Surface Area Reduction



Contributing Factors⁹: Polymorbid Poly Pharmacy



LHACM*: Trilayer Human Placental Allograft



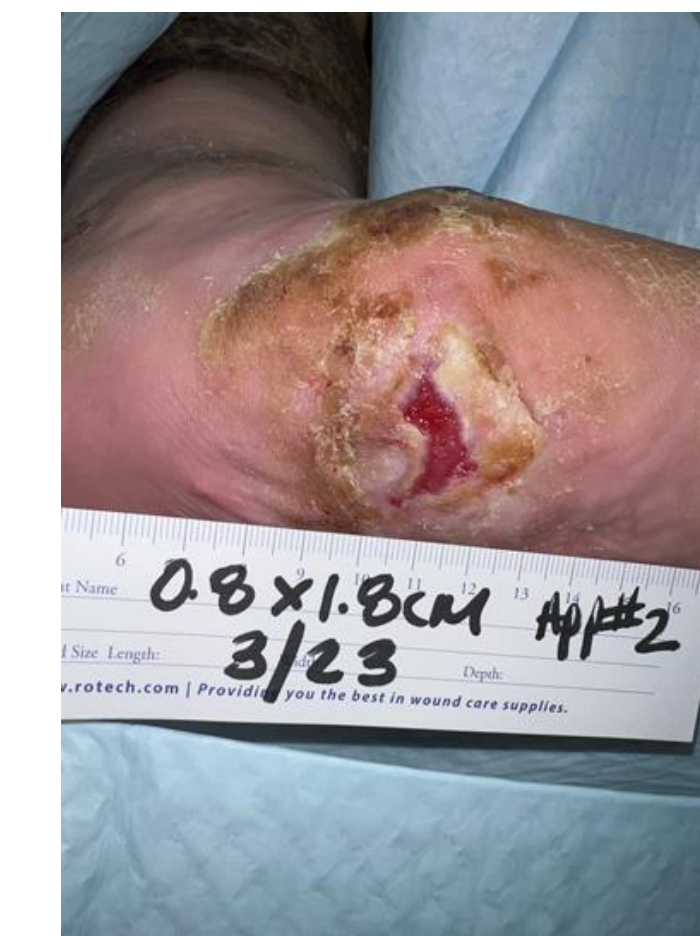0.6 um Thick

- Novel Trilayer Tissue:
 - Amnion
 - Intermediate Layer
 - Chorion
- Suturable
- Repositionable when dry or hydrated

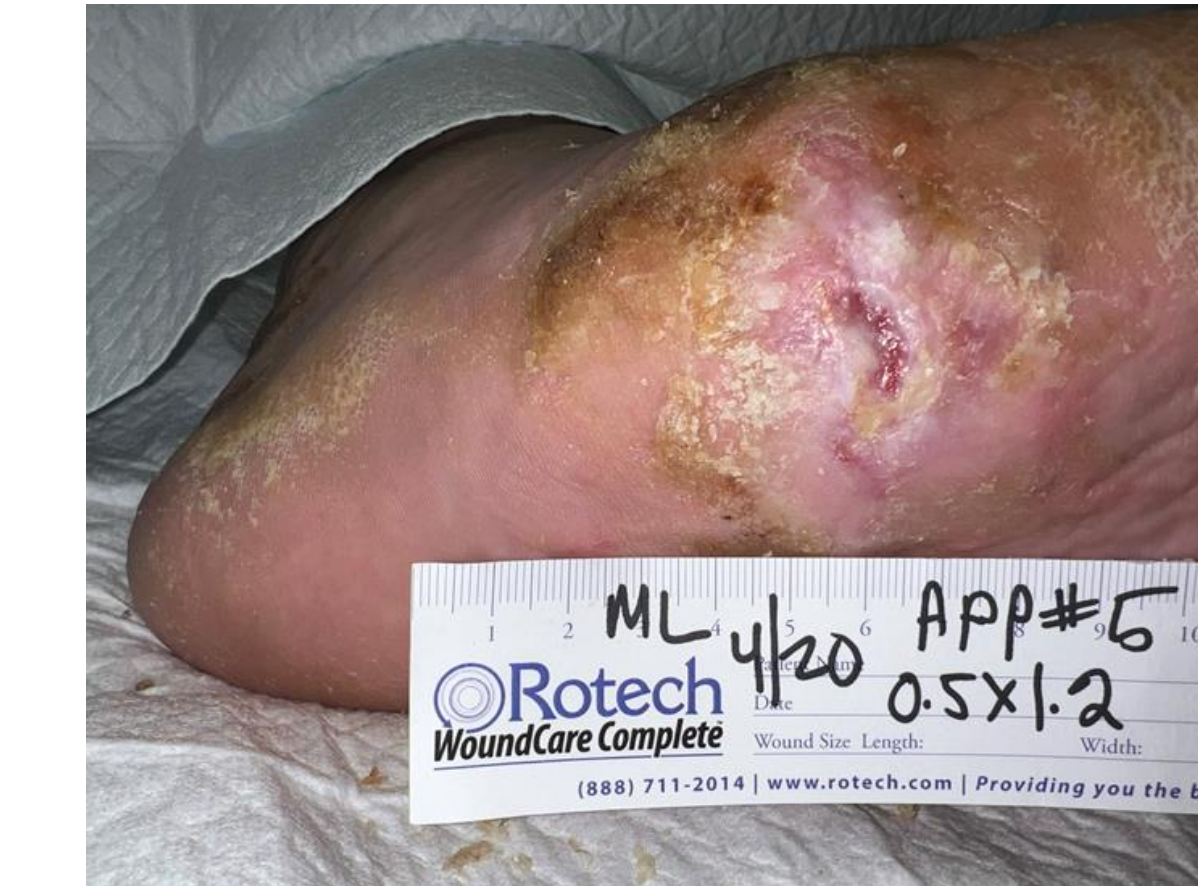64-Year-Old Male: Grade 3 Chronic DFU (15 –weeks)

Neuropathic induced Imbalance
Fall 3-Months after 1st Evaluation
Charcot Deformity
Hypertension
Hyperlipidemia
Asthma
Polypharmacy (16 medications)

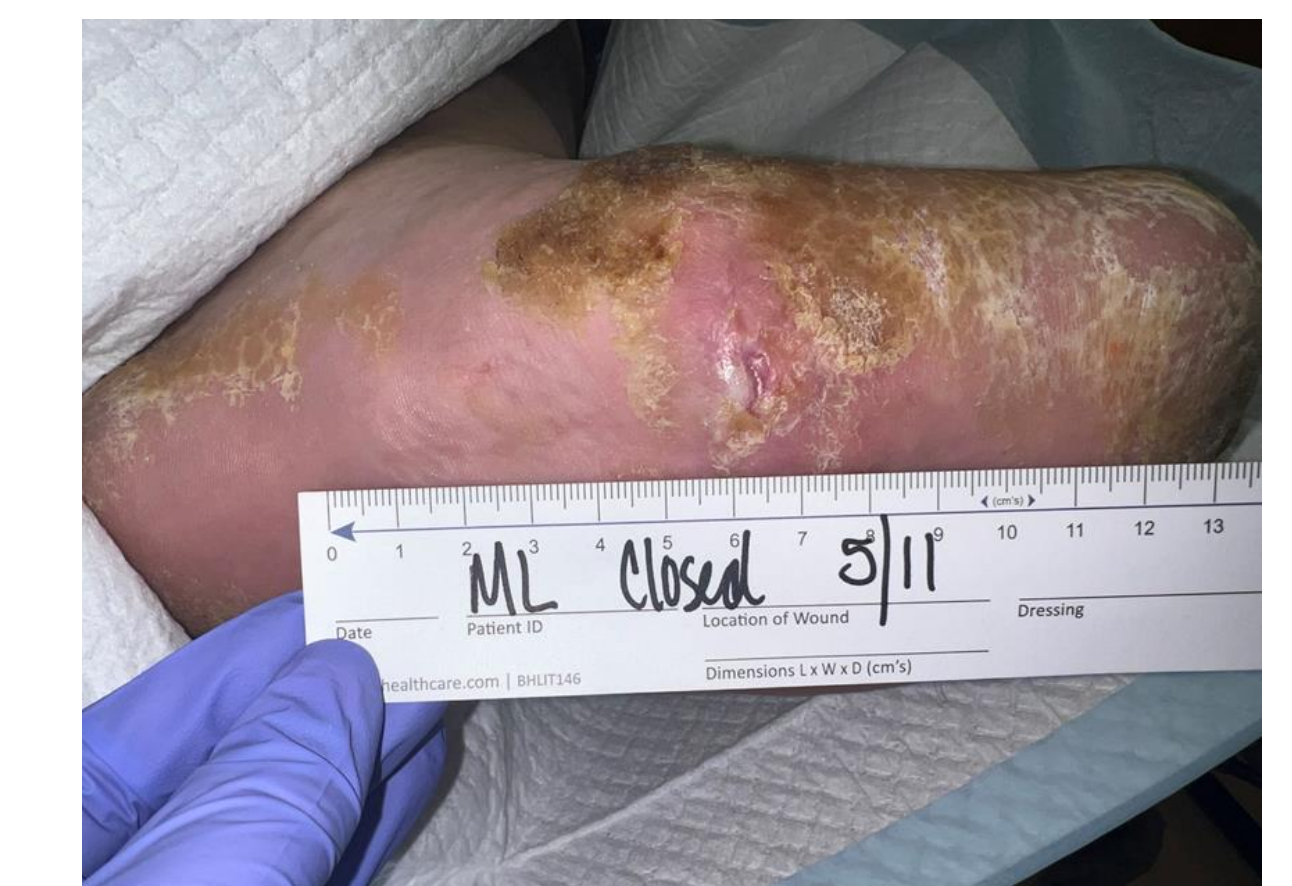	Wound Size	Wound Improvement
First Application	1.0 x 2.5 cm	
Second Application	0.8 x 1.8 cm	42%
Third Application	0.6 x 1.8 cm	57%
Fourth Application	0.5 x 1.3 cm	74%
Fifth Application	0.5 X 1.2 cm	76%



2nd Application



5th Application

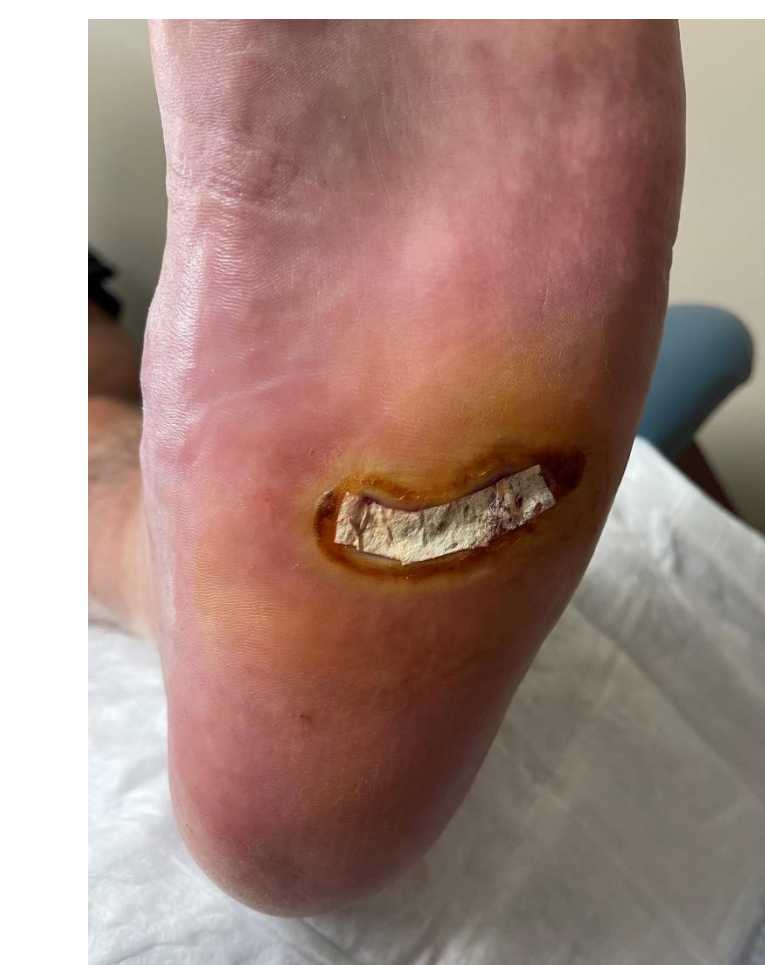

Closed

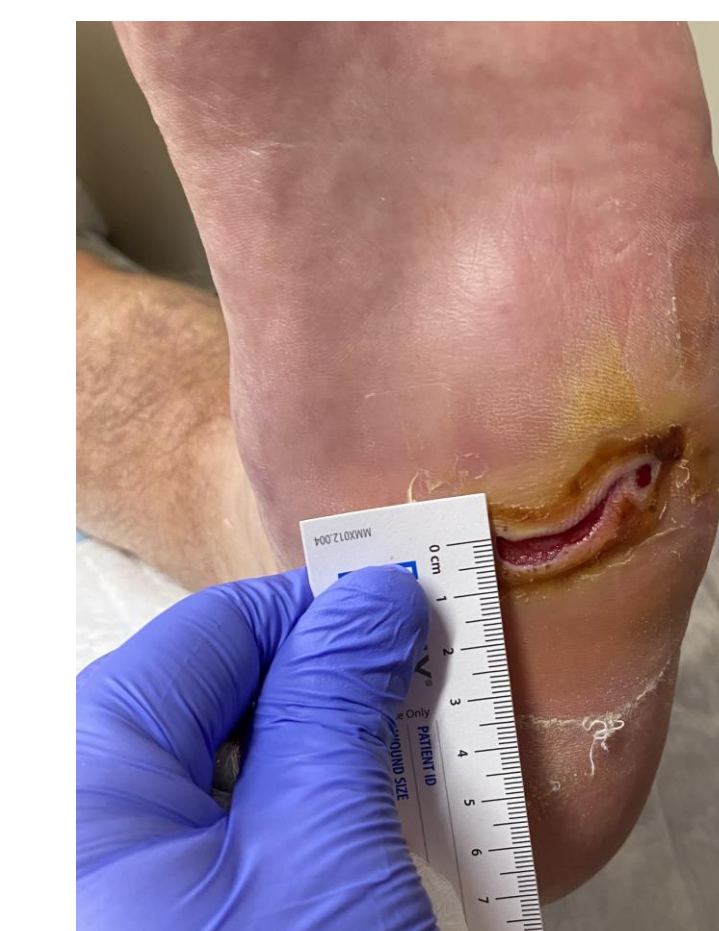66-Year-Old Male: Grade 3 Chronic DFU (3- Years)

Moderate Obesity
Charcot Deformity
Peripheral Neuropathy
Hypertension
Hyperlipidemia
Current Smoker (1/2 – 1 Pack per day)
Hypothyroidism
AFO Brace
Polypharmacy (17 Medications)
Peripheral Arterial Disease

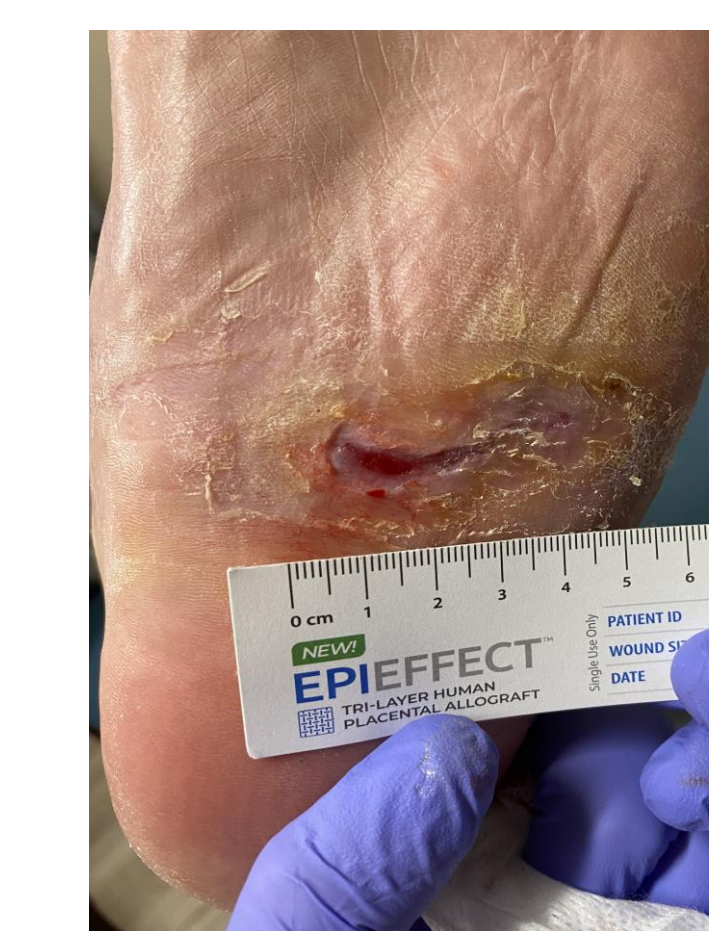	Wound Size	Wound Improvement
First Application	3.8 X 1.1 cm	
Second Application	2.7 X 0.6 cm	61%
Third Application	1.8 X 0.3 cm	83%
Fourth Application	0.7 X 0.4	99.3%



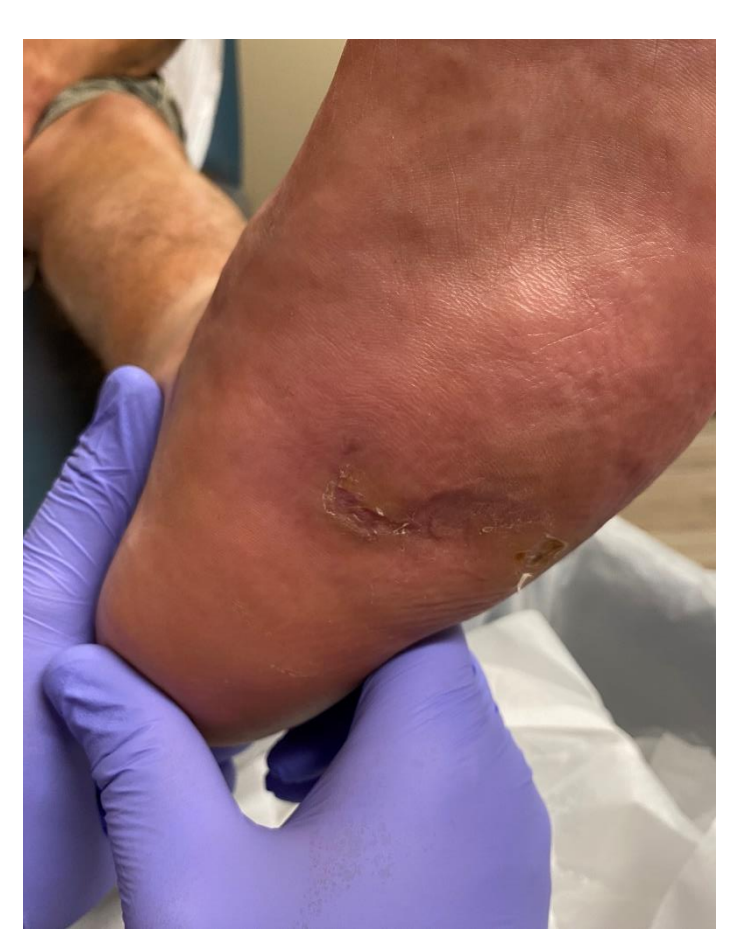1st Application



2nd Application



3rd Application



Closed in 30 Days after 4 Applications

References

- Marissa J. Carter, Joan DaVanzo, Randall Haught, Marcia Nusgart, Donna Cartwright & Caroline E. Fife (2023) Chronic wound prevalence and the associated cost of treatment in Medicare beneficiaries: changes between 2014 and 2019, Journal of Medical Economics, 26:1, 894-901, DOI: 10.1080/13696998.2023.2232256
- ElSayed NA, Aleppo G, Aroda VR, et al. 2. Classification and Diagnosis of Diabetes: Standards of Care in Diabetes-2023 [published correction appears in Diabetes Care. 2023 Feb 01;:] [published correction appears in Diabetes Care. 2023 Sep 1;46(9):1715]. Diabetes Care. 2023;46(Suppl 1):S19-S40. doi:10.2337/dc23-S0022.
- Singh N, Armstrong DG, Lipsky BA. Preventing Foot Ulcers in Patients With Diabetes. JAMA. 2005;293(2):217-228. doi:10.1001/jama.293.2.217
- Atkin L, Bucko Z, Conde Montero E, Cutting K, Moffat C, Probst A, Romanelli M, Schultz GS, Tettelbach W. Implementing TIMERS: the race against hard-to-heal wounds. J Wound Care 2019;28(3 Suppl 3):S1-S49
- Sheehan P, Jones P, Caselli A, Giurini JM, Veves A. Percent change in wound area of diabetic foot ulcers over a 4-week period is a robust predictor of complete healing in a 12-week prospective trial. Diabetes Care. 2003;26(6):1879-1882.

- Rayman G, Akpan A, Cowie M, et al. Managing patients with comorbidities: future models of care. Future Healthc J. 2022;9(2):101-105. doi:10.7861/fhj.2022-00
- Armstrong DG, Tettelbach WH, Chang TJ, et al. Observed impact of skin substitutes in lower extremity diabetic ulcers: lessons from the Medicare Database (2015-2018). J Wound Care. 2021;30(Sup7):S5-S16. doi:10.12968/jowc.2021.30.Sup7.S5
- Tettelbach WH, Armstrong DG, Chang TJ, et al. Cost-effectiveness of dehydrated human amnion/chorion membrane allografts in lower extremity diabetic ulcer treatment. J Wound Care. 2022;31(Sup2):S10-S31. doi:10.12968/jowc.2022.31.Sup2.S10
- Tettelbach WH, Driver V, Oropallo A, et al. Treatment patterns and outcomes of Medicare enrollees who developed venous leg ulcers. J Wound Care. 2023;32(11):704-718. doi:10.12968/jowc.2023.32.11.704

KEY: *LHACM = EPIEFFECT (MiMedx Group, Inc, Marietta, GA)

DISCLOSURES: Poster development supported by MIMEDX Group, Inc

LHACM*: Trilayer Human Placental Allograft



- **Novel Trilayer Tissue:**
 - Amnion
 - Intermediate Layer
 - Chorion
- **Suturable**
- **Repositionable when dry or hydrated**

0.6 um Thick