



# THE COMBINED USE OF SUCROSE OCTASULFATE WITH TLCAG HEALING MATRIX AND POLYABSORBENT FIBERS

SÃO JOÃO

## IN THE DEBRIDEMENT OF NON-VIABLE TISSUE

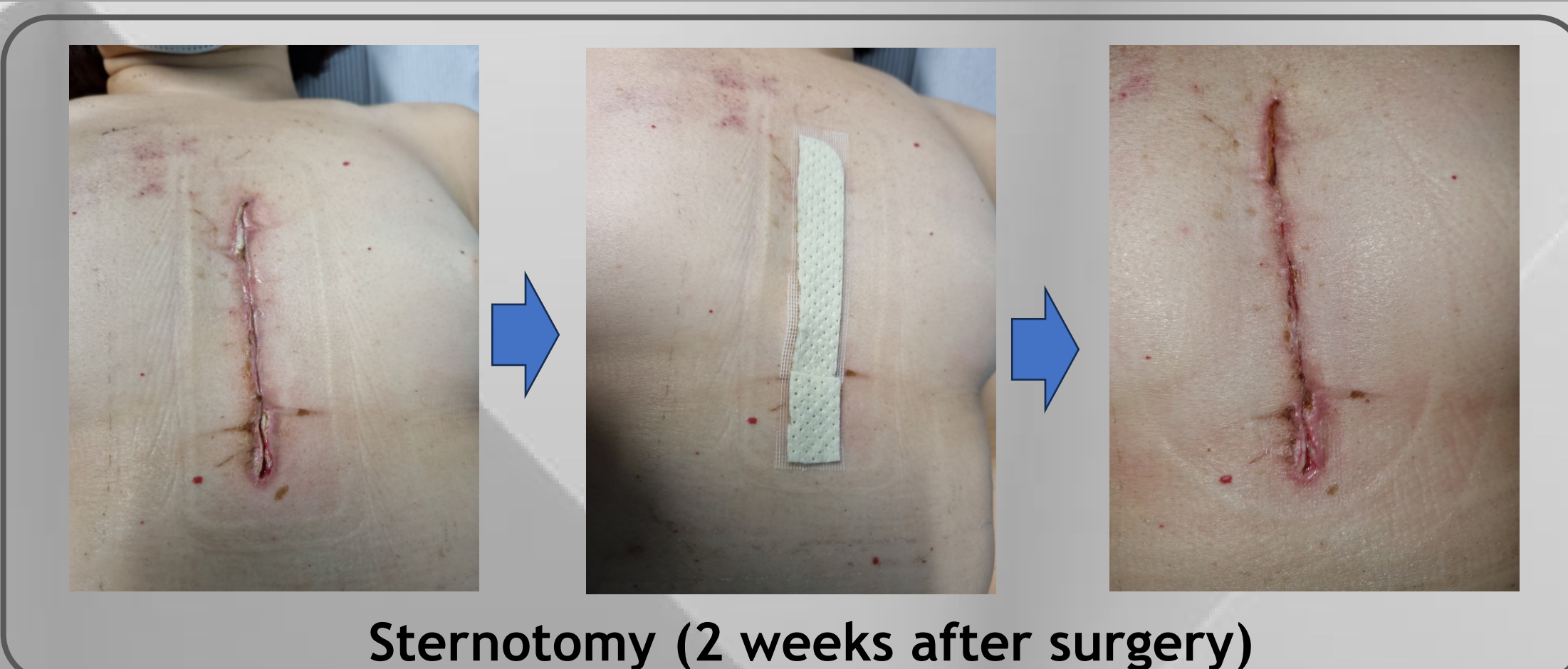CS-065

GONÇALVES, VIVIANA<sup>1</sup>

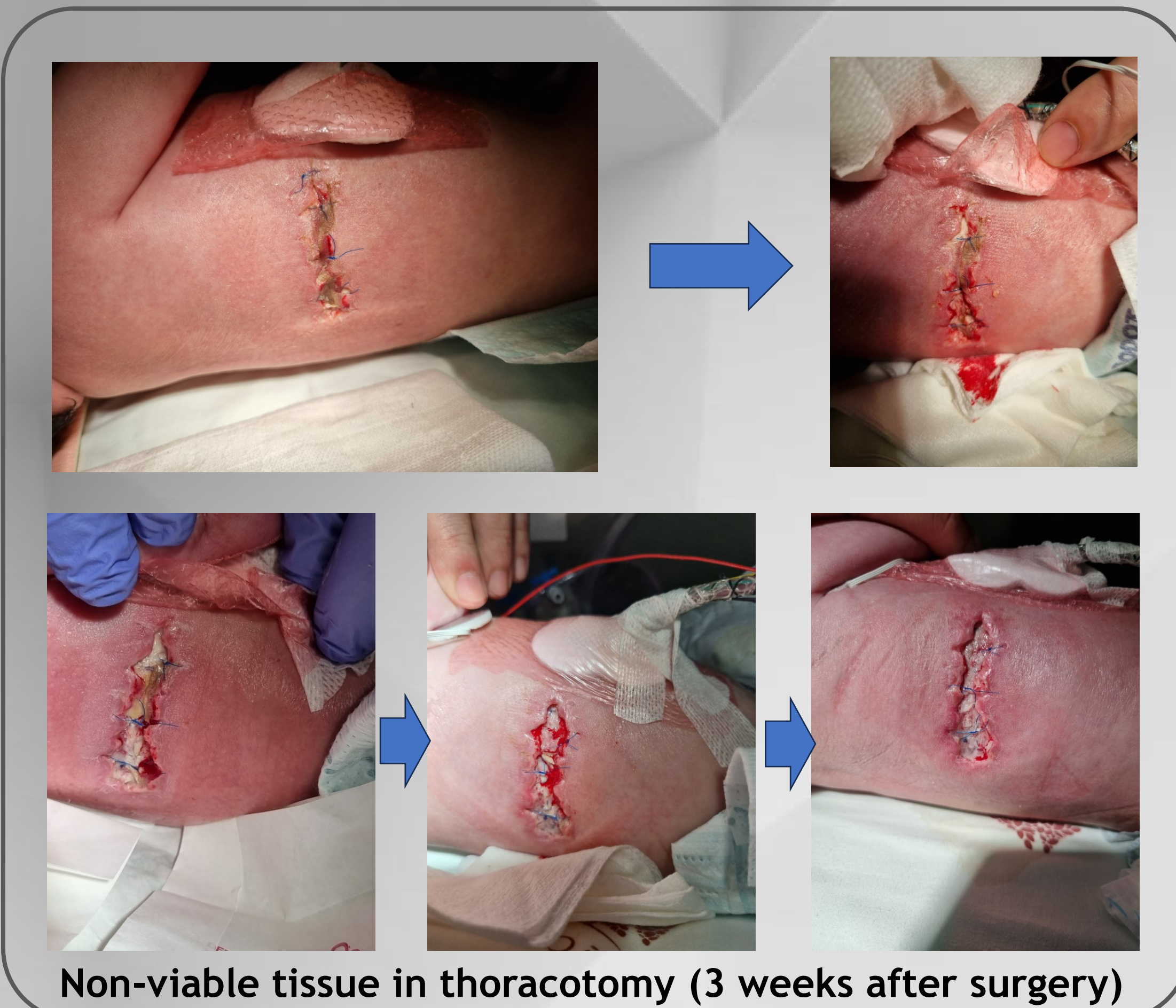
SAWC Spring | WHS | May 14-18 | Orlando, FL

1. TISSUE VIABILITY NURSE OF CARDIOTHORACIC SURGERY ; MSN - CENTRO HOSPITALAR E UNIVERSITÁRIO SÃO JOÃO, PORTO, PORTUGAL

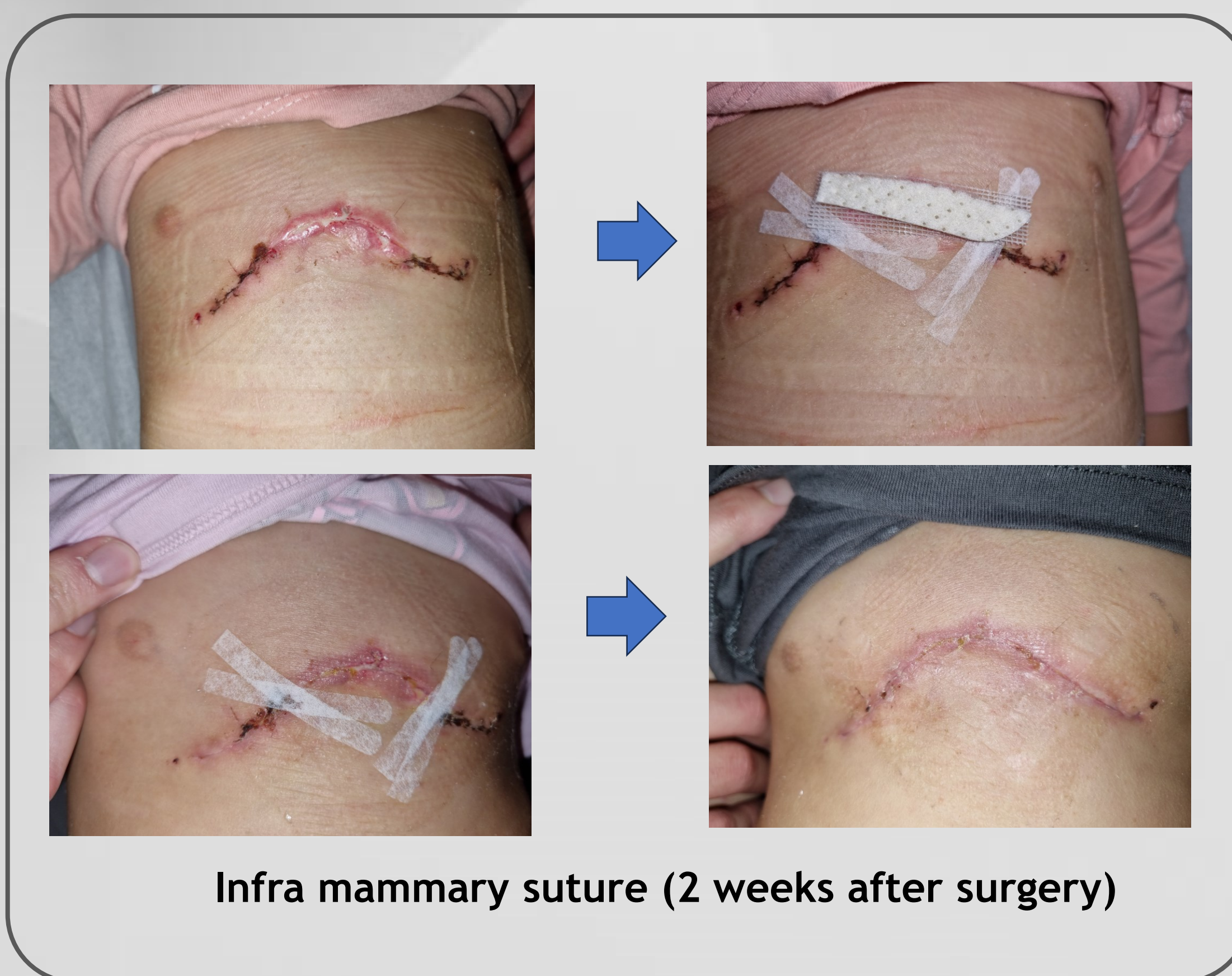
The presence of non-viable tissue in the wound bed is a physical barrier to healing, and debridement should be the primary intervention. The combined use of sucrose octasulfate with TLC-Ag healing matrix and polyabsorbent fibers showed a superior ability to debride non-viable tissue, protecting the edges and granulation tissue, compared to the exclusive use of TLC-Ag healing matrix.



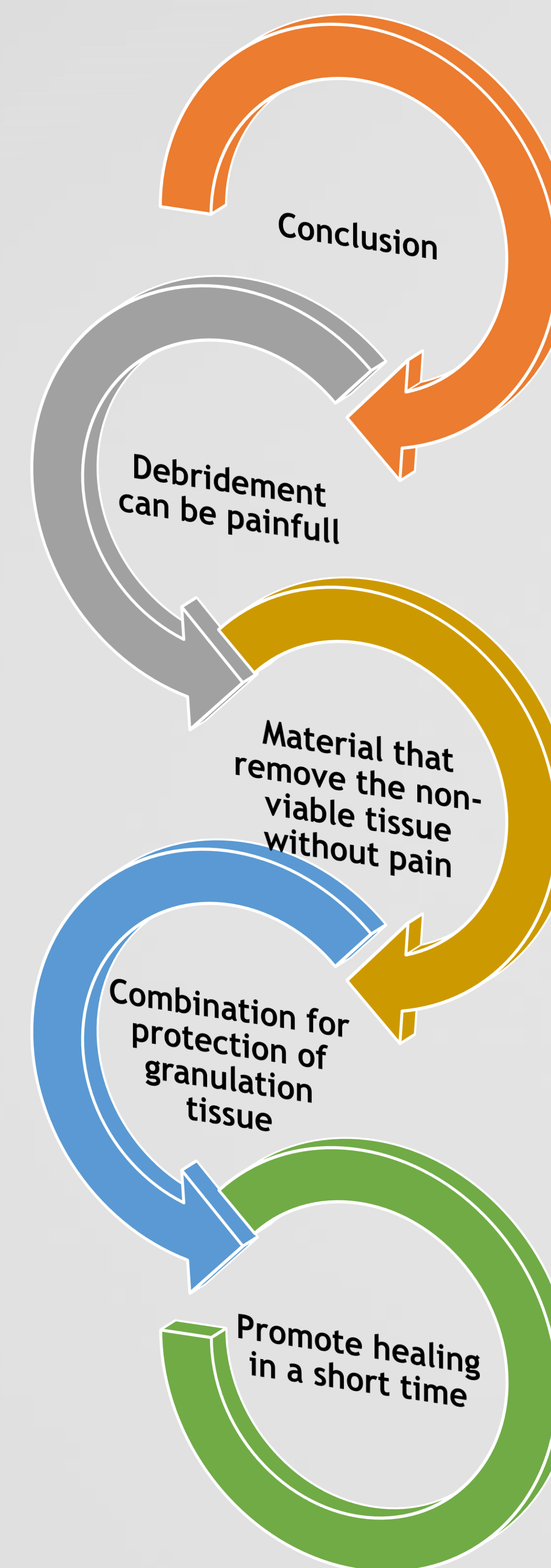
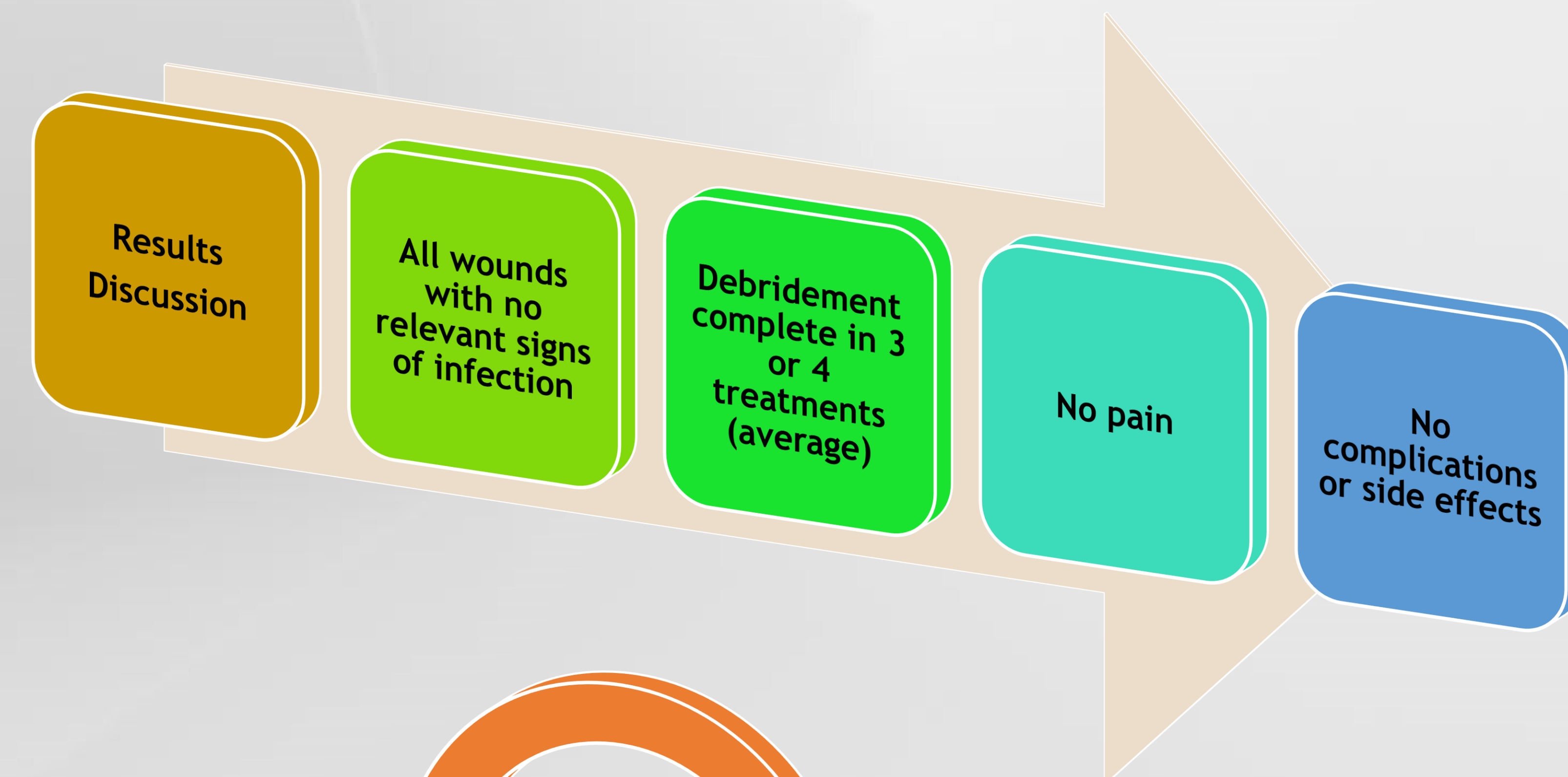
Sternotomy (2 weeks after surgery)



Non-viable tissue in thoracotomy (3 weeks after surgery)



Infra mammary suture (2 weeks after surgery)



### Case series

- Adults, paediatrics and neonates

### Adults - 30 cases

- Surgical Wounds and burn

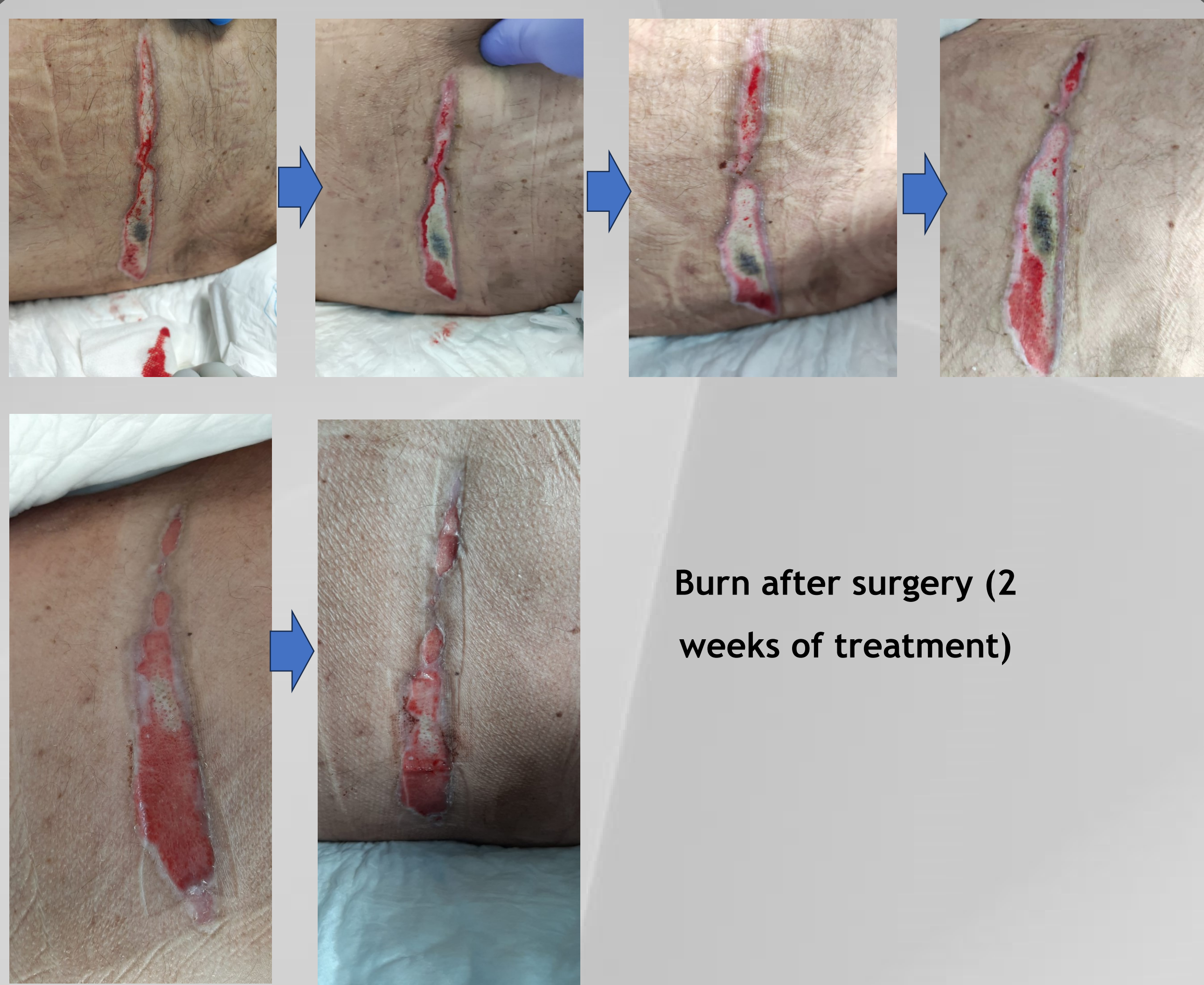### Paediatrics - 10 cases

- Surgical Wounds

### Neonates - 12 cases

- Surgical Wounds

Case series were carried out, in wounds of adults, children and neonates, with the objective of demonstrating the effectiveness of this procedure, with reduction of pain in the debridement and improvement of quality of life, using this combination until complete debridement of non-viable tissue, without any other debridement technique. Polyurethane was used as a dressing for exudate management. In some cases we made the association of topical oxygen therapy, mainly in neonates.



Burn after surgery (2 weeks of treatment)

### References

Edmonds, M. et al (2018) Sucrose octasulfate dressing versus control dressing in patients with neuroischaemic diabetic foot ulcers (Explorer): an international, multicentre, double-blind, randomised, controlled trial. *The Lancet Diabetes & Endocrinology*, 6(3), 186-196, 2018

Nair, H. et al (2021) Benefits of sucrose octasulfate (TLC-NOSF) dressings in the treatment of chronic wounds: a systematic review. *J Wound Care Adv* 36(5):542-552.

Meloni, M. et al (2022) Effectiveness of Sucrose Octasulfate Dressing in the Treatment of Neuro-Ischaemic Diabetic Foot Heel Ulcers: A Retrospective Single arm Study. *Int. J Low Extrem Wounds*, Mar. 15:15347346221087499.

Galea, E.; Khatib, M. (2020) Addressing wound chronicity factors: UrgoClean Ag® and UrgoStart® case studies. *Wounds Middle East* Vol 7 Issue 1; Wounds International 2020

Sigal, M. (2019) Evaluation of TLC-NOSF dressing with poly-absorbent fibres in exuding leg ulcers: two multicentric, single-arm, prospective, open-label clinical trials. *Journal of Wound Care* Vol 28, n. 3

Ciprandi et al (2022) - Neonatal and Pediatric Wound Care. 1<sup>st</sup> edition, Edizioni Minerva Medica

Mounoury, F. et al. (2021) Cost-effectiveness of TLC-NOSF dressings versus neutral dressings for the treatment of diabetic foot ulcers in France. *PLoS ONE* 16(11): e0245652