

Statement of Purpose

This case series involves 7 patients sustaining diabetic or surgical wounds in the watershed area with tendon exposure that were healed with application of fish skin xenografts. The aim of this study is to exhibit success of the Kerecis Omega-3 xenograft in healing large, complicated soft tissue deficits in the presence of multiple comorbidities.

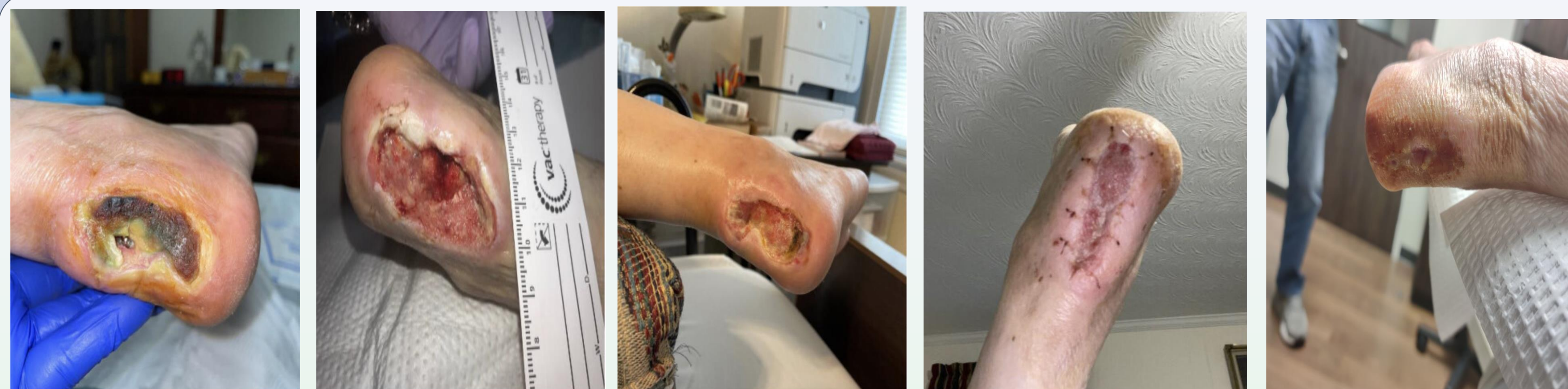Introduction

The Achilles tendon region is noted to be a historically complex area to heal wounds due to its known poor vascular supply.¹ Multiple different theories have been proposed of the exact angiosome supply to this region, most famously by Taylor and Attinger¹. Literature confirms significant risk factors predisposing individuals to wound complications such as current tobacco use, current steroid use, and female sex.² While there has been conflicting research in the exact distribution, the watershed area located 2-6 cm proximal to the insertion is undoubtedly a vexatious area to heal once a wound has formed due to its known avascularity.^{3,4,5,6}

Superimposed with poor subcutaneous tissue in the anatomic region, these wounds are often detrimental due to vast tendon exposure if not managed properly. Larger deficits commonly require negative pressure wound therapy in order establish a granular and suitable base for skin epithelialization.⁷ Literature supports upwards of 12 weeks of continuous negative pressure therapy in cases where the Achilles tendon is exposed in order to obtain a suitable wound bed to incorporate a skin substitute or graft.

Increased healing of wounds with Omega-3 fatty acid skin substitutes have the potential to lead to less analgesic use due to their ability to minimize the inflammatory process of wound healing. This stage of wound progression is often known to be prolonged in most chronic, non-healing wounds.⁸

An additional potential complication associated with graft incorporation is the presence of latent or chronic infection. In many cases, the only way to obtain surgical cure for these aggressive infections in the lower extremity in the lower extremity is a proximal amputation. Previous have studies have shown success in the use of Omega-3 xenografts being used in the setting of chronic osteomyelitis, which a patient in this case series suffered from, but fortunately progressed to full skin epithelialization.⁹

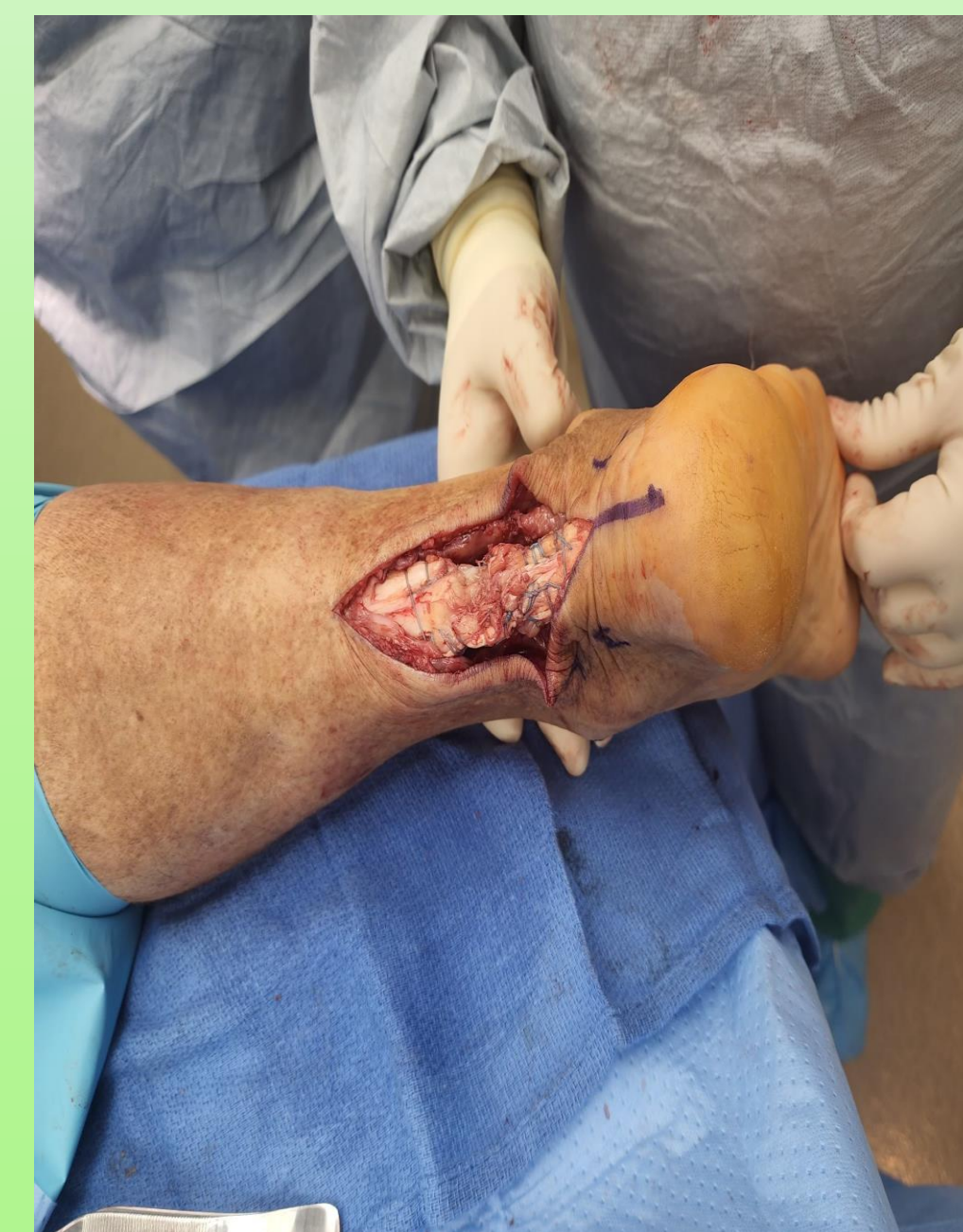


Methods

Seven subjects were included in the case series with all possessing wounds to the Achilles tendon region following surgery or from a diabetic/pressure ulceration. Patients were selected from an initial presentation date of July 1, 2021 through August 31, 2023. Demographics consisted of 5 females, 2 males, with an average age of 50.2 years (range 38-72). Pertinent comorbidities included in the study and number of patients being affected included diabetes (5), peripheral artery disease (2), hypertension (6), hyperlipidemia (5), congestive heart failure (1) and tobacco used disorder (4). All surgical wounds were defined as acute ad due in part due to surgical dehiscence. Surgical procedures included were 1 calcaneus fracture and 3 retrocalcaneal exostosis with Achilles detachment and reattachment and 1 Achilles rupture repair. Serial debridements with osseous and soft tissue resections, along with negative pressure wound therapy were implemented as deemed necessary for all patients. washouts were performed when necessary, in addition to negative pressure assisted therapy via wound vacuums in 57% of the subjects. Grafts were cut and layered in areas where extensive deficits were present, and tunneling areas were filled with graft in granule form. When necessary, infectious disease consultations were placed for multi-drug resistant infections as well as for positive proximal margins for a microbiology and pathology standpoint. The subject pool for the aforementioned included two patients who both received a PICC line with a 6-week course of antibiotics guided by intraoperative cultures. Patients remained non-weight bearing to the affected limb in a CAM boot for the duration of graft applications to prevent failure of graft uptake during graft incorporation phases.

Results

All seven patients have progressed to full healing of their respective wounds with fish skin grafts being used as the only skin substitute to facilitate tissue coverage. Three of the seven patient patients required application of negative pressure therapy due to excessive tendon exposure. The average wound size was measured at 4.78 cm² (range 1.6 cm² – 8.9cm²) upon initial presentation. Zero of the seven patients undergoing complete skin epithelialization have undergone wound recurrence with an average follow up of 24 weeks (6 weeks – 47 weeks) An average of 2.75 graft applications (range 1.0 - 4.0) were applied per patient with a direct correlation being observed with increase applications to larger wound measurements. Average time to complete healing was measured at 16.4 weeks (range 7 weeks - 22 weeks) for those undergoing complete healing. Both patients with PAD underwent angiograms with increased runoff following vascular intervention and an average of 0.19 improvement in ABI.



Achilles tendon exposure following acute repair

Discussion

This case series exhibits an excellent success rate in the healing of Achilles wounds with Kerecis Omega-3 grafting. Although possessing a small sample size, the success rate exhibits promise for advanced limb salvage for wounds in extremely problematic areas, including those with multiple comorbidities inhibiting healing. Additional pitfalls of this case series include no randomization, no independent variables, and no comparative similar case series to extrapolate data from in terms of similar patient cohort and graft usage.

Further research is essential via randomized control trials and/or cohort studies to evaluate the efficacy of fish skin xenografts with obtainable statistical significance for variables such as optimal graft application timing for serial applications and the incorporation of NPWT in conjunction with grafting during the incorporation phase. All patients in this study undergoing NPWT had therapy completed prior to graft application and for no patients did simultaneous use occur. This case series lays the foundation for such further studies to take place and provides aspirations for those suffering extensive tissue loss that limb salvage is possible despite non-optimal and complicated healing conditions.

References

- Attinger CE, Evans KK, Bulan E, Blume P, Cooper P. Angiosomes of the foot and ankle and clinical implications for limb salvage: reconstruction, incisions, and revascularization. *Plast Reconstr Surg.* 2006 Jun;117(7 Suppl):261S-293S. doi: 10.1097/01.prs.0000222582.84385.54.
- Bruggeman, Nicholas B MD; Turner, Norman S MD; Dahm, Diane L MD; Voll, Anthony E RN; Hoskin, Tanya L MS; Jacofsky, David J MD; Haidukewych, George J MD. Wound Complications after Open Achilles Tendon Repair: An Analysis of Risk Factors. *Clinical Orthopaedics and Related Research* 427(p 63-66, October 2004. | DOI: 10.1097/01.blo.0000144475.05543.e7
- Lagergren C, Lindholm A. 1959. Vascular distribution in the Achilles tendon; an angiographic and microangiographic study. *Acta Chir Scand* 116:491-495.
- Pufe T, Petersen WJ, Mentlein R, Tillmann BN. 2005. The role of vasculature and angiogenesis for the pathogenesis of degenerative tendons disease. *Scand J Med Sci Sports* 15:211-222.
- Schmidt-Rohlfing B, Graf J, Schneider U, Niethard FU. 1992. The blood supply of the Achilles tendon. *Int Orthop* 16:29-31.
- Taylor GI. The angiosomes of the body and their supply to perforator flaps. *Clin Plast Surg.* 2003 Jul;30(3):331-42. v. doi: 10.1016/s0094-1298(03)00034-8.
- Judson R, Heugel, Kare Sias Parks, Sara S. Christie, Joseph F. Pulito, Daniel H. Zegzula, Nathan A. Kemalyan. Treatment of the Exposed Achilles Tendon Using Negative Pressure Wound Therapy: A Case Report. *The Journal of Burn Care & Rehabilitation*, Volume 23, Issue 3, May-June 2002, Pages 167-171. <https://doi.org/10.1097/00004630-200205000-00005>
- Ramanujam, C. L., & Zgonis, T. (2012). Surgical soft tissue closure of severe diabetic foot infections: a combination of biologics, negative pressure wound therapy, and skin grafting. *Clinics in podiatric medicine and surgery*, 29(1), 143-146.
- Holl, J., Kowalewski, C., Zimek, Z., Fiedor, P., Kaminski, A., Oldak, T., ... & Eljaszewicz, A. (2021). Chronic diabetic wounds and their treatment with skin substitutes. *Cells*, 10(3), 655.