

# Elimination of Biofilms and Pathogens by the Rebalancing of the Wound Bed's Bioelectric Charge

Charles Andersen, MD, FACS, FSVS, MAPWCA; Robert G. Frykberg, DPM, MPH

## AgFresh® – Moleculight Cases

The loss of the bioelectric balance in the wound bed leads to unresolved chronic wounds with inherent biofilms and bacterial colonization. The chronic wound bed is characterized as a negatively charged (anionic) environment. The negatively charged molecules include the membranes of bacteria, biofilms and the anchoring mechanism of the biofilm to the wound bed. In order to remove anionic obstacles to wound healing, a rebalancing needs to take place with the introduction of positively charged (cationic) nano-particle minerals that bind and inactivate anions through an electron attraction process.

## McCord System

- Fentonite® – a combination of cationic nano-particle minerals releases a unique balance of cations that have been proven to bind with the anionic biofilms and pathogens causing the loss of their ability to defend themselves due to their permanent membrane deconstruction.
- The following cases represent results utilizing the McCord System with Fentonite®

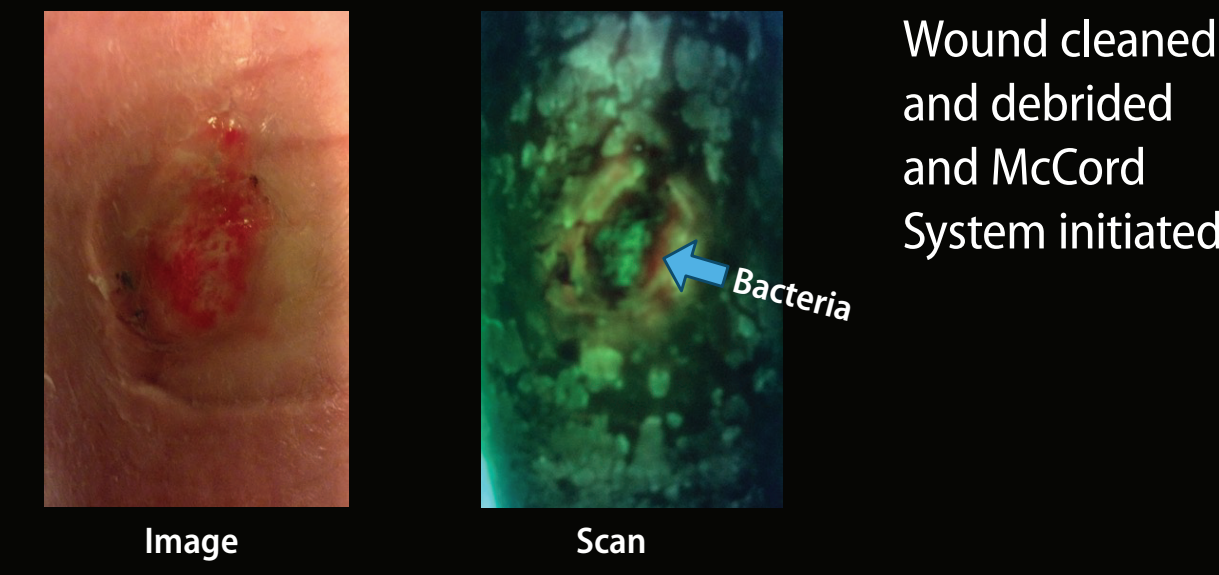
## Clinic Protocol for McCord System

- Clean wound with non-ionic cleaner
- Baseline Moleculight scan
- Debride and cleanse with attempts to remove bacteria if possible (Only clean with non-ionic solution)
- Repeat bacterial scan
- Hydrate wound with BioCleanse™
- Apply BioRelease®
- Apply AGFresh®
- Apply secondary dressing and compression or off-loading if appropriate
- Change dressing twice per week
- With dressing changes clean with non-ionic cleaner and debride as necessary
- Scan for bacteria pre- and post-debridement

## CASE 1 - EC

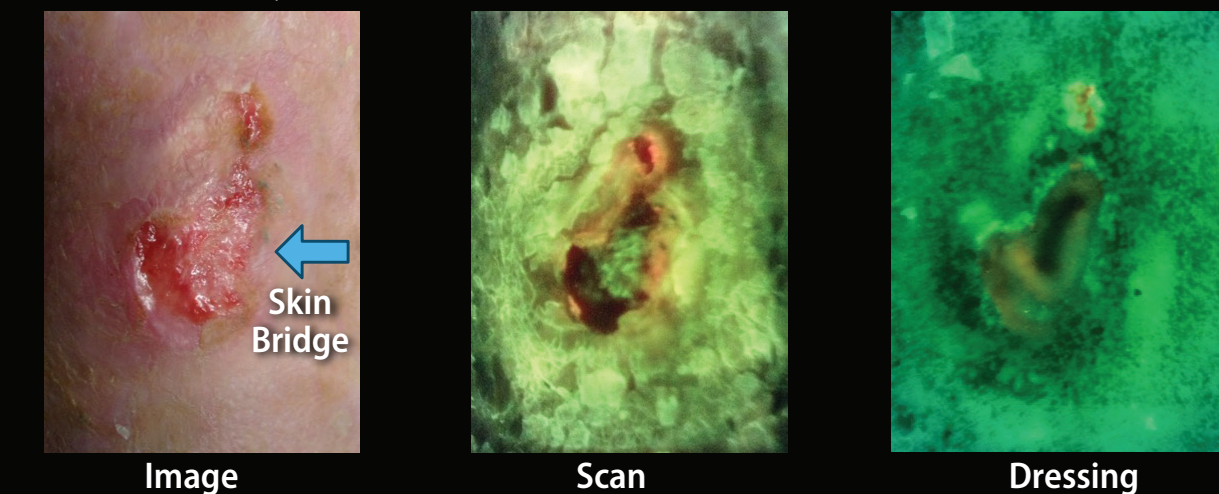
- Chronic edema with an edema ulcer right leg
- Wound failed to progress with standard wound care
- 10/12/2023 – Started on McCord System

### EC – Pre-Application



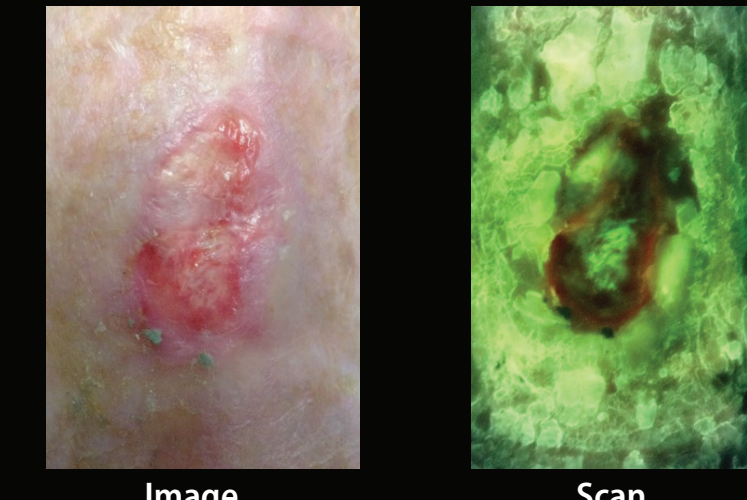
Wound cleaned and debrided and McCord System initiated

### EC – 8 Days

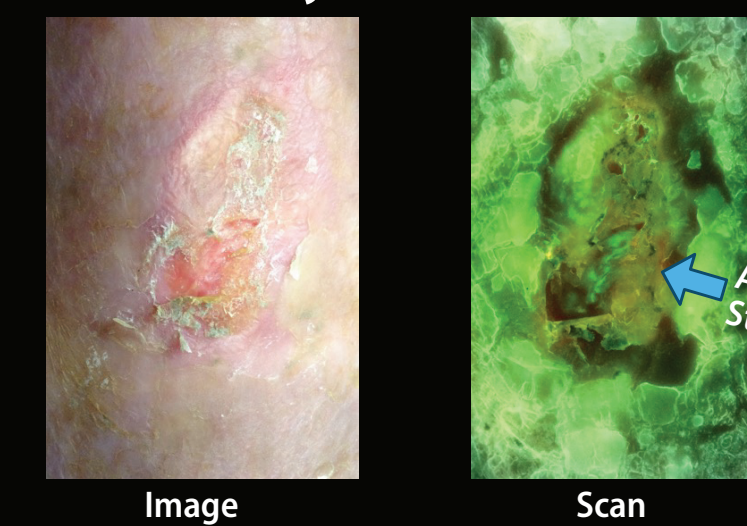


Wound cleaned and debrided with removal of bacteria. Wound re-dressed with McCord System. Two-layer Coban® wrap applied

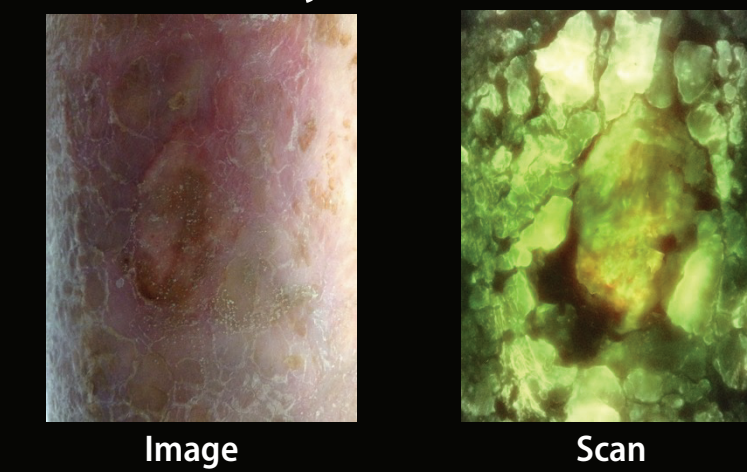
### EC – 12 Days



### EC – 19 Days



### EC – 41 Days

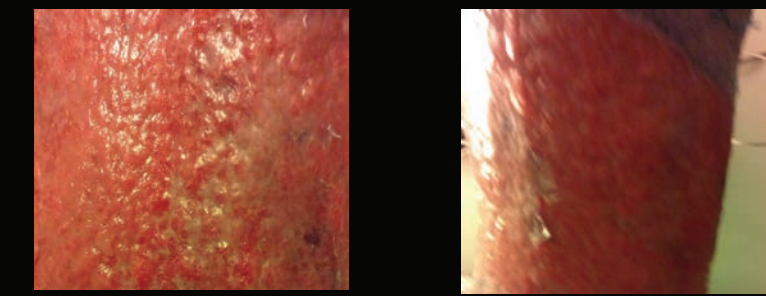


Chronic lower extremity edema wound that healed in 41 days with the McCord System.

## CASE 2 - DF

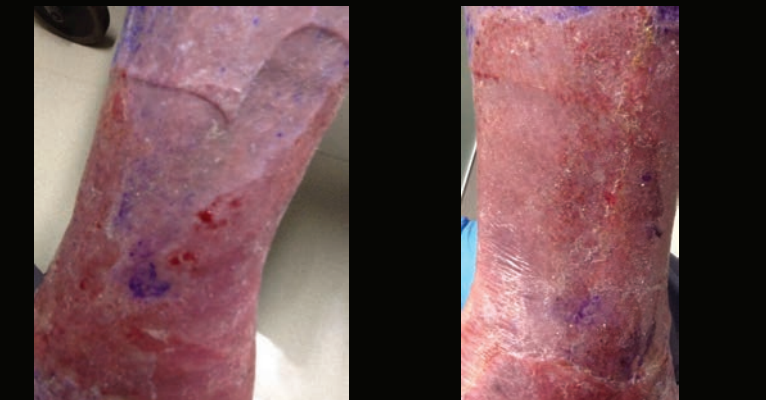
- 74 y/o male – Six-month history of right lower extremity edema ulcers with fragile erythematous skin surface and superficial ulcerations with exudate going through Hydrofera Blue®, XLT® and a two-layer Coban® wrap. Cultures demonstrated pseudomonas resistant to all oral antibiotics
- Patient being seen in the outpatient wound care clinic weekly or biweekly for assessment and replacement of his compression wraps

### DF – Pre-Treatment



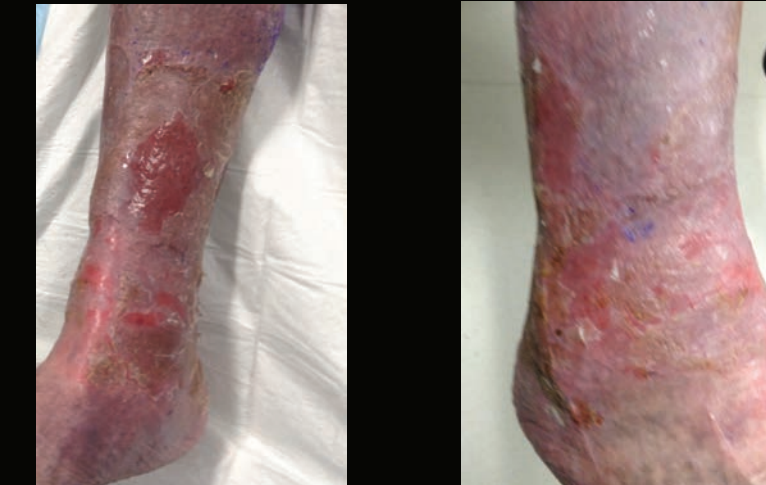Erythematous, fragile very exudative skin with superficial ulcerations

### DF – 24 Hours – Post-treatment



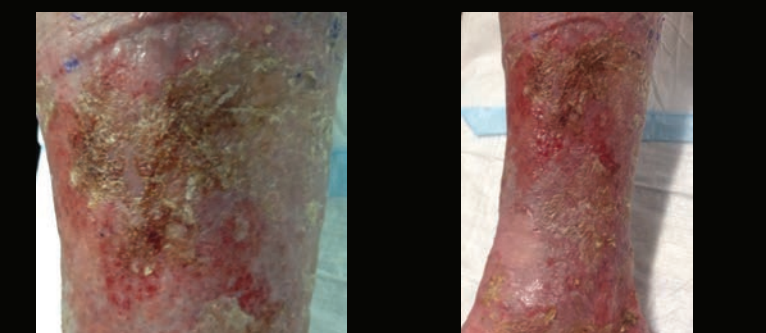
After 24 hours, surface was smooth with less erythema and normal looking skin. Significant decrease in exudate and bacteria

### DF – 6 Days

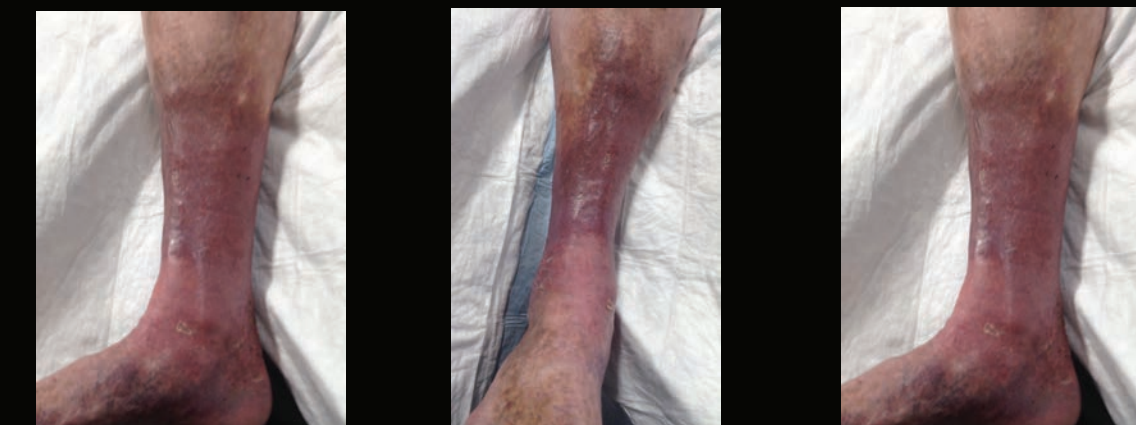

Clinically no pain  
Minimal exudate  
Skin intact  
Compression wraps discontinued  
Removal of superficial dry skin demonstrated intact skin

### DF – 14 Days



### DF – 38 Days

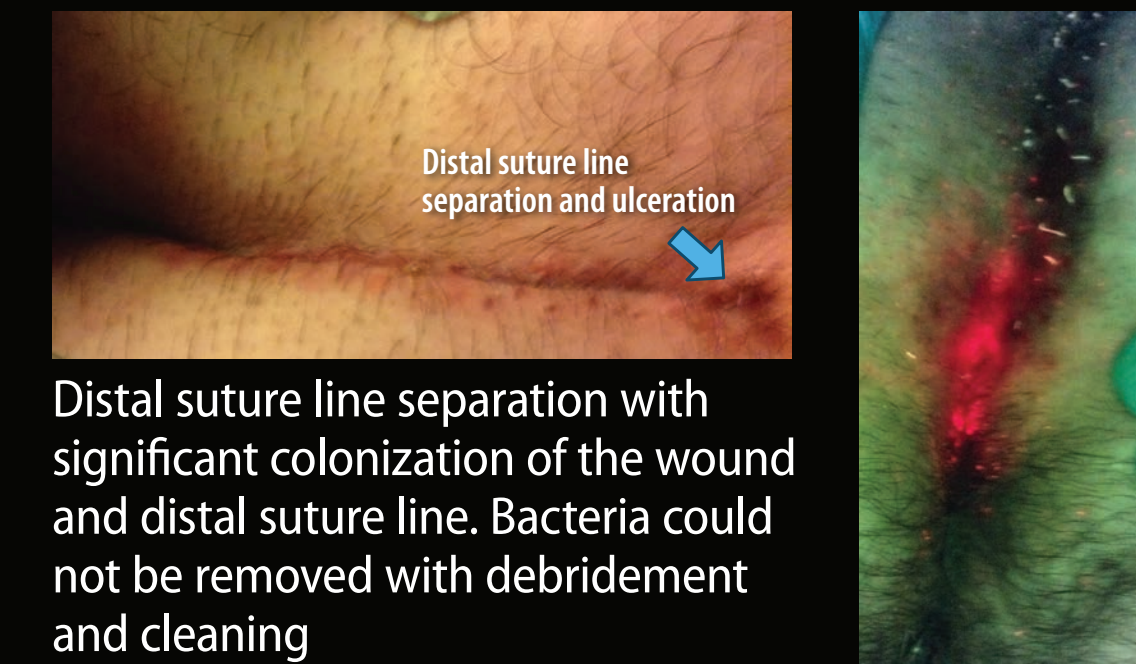


- After 24 hours of therapy the skin was markedly improved with resolution of the erythematous and fragile skin and wounds that had been present for 6 months
- After 14 days the scans for pseudomonas were negative
- On follow-up visits the dry skin separated revealing intact skin that was not fragile, erythematous or exudative.
- After 38 days he transitioned from active compression to graded support stockings

## CASE 3 - AA

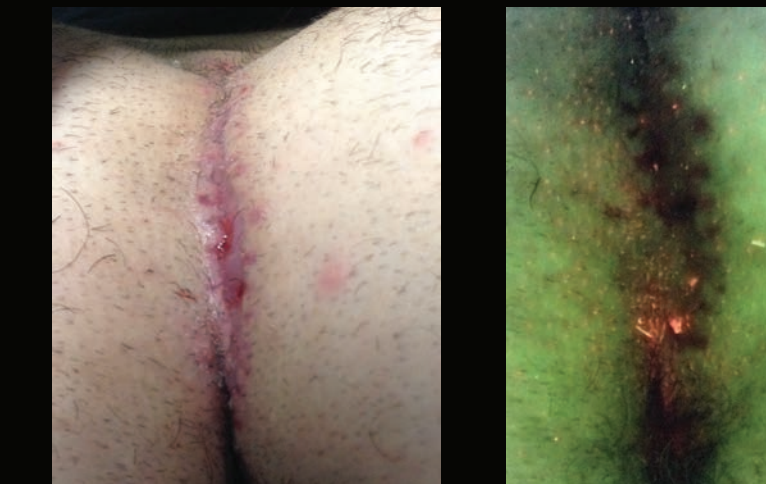
- 16 y/o male with long standing pilonidal disease associated with intermittent abscess formation
- Patient had excision of his pilonidal disease with primary closure
- This type of surgery has a high incidence of suture line complications
- Referred to wound care clinic for treatment of a suture line complications

### AA – Baseline



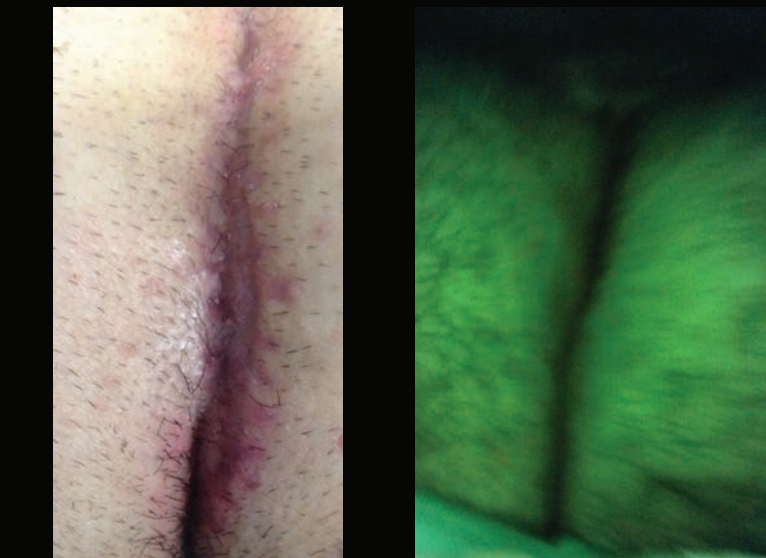
Distal suture line separation with significant colonization of the wound and distal suture line. Bacteria could not be removed with debridement and cleaning

### AA – 6 Days



Size of ulcer has decreased by 50%  
Bacterial burden significantly decreased  
Patient continued to do daily treatment at home following a shower with foam soap

### AA – 14 Days



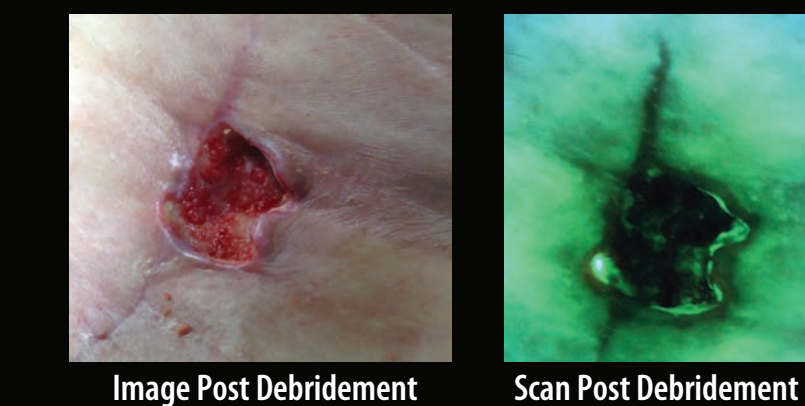
Incision healed with a negative bacterial scan  
Success in a suture line exposed to a dirty environment  
No further breakdown of the suture line

- Excision of pilonidal disease with primary closure is associated with very high rate of suture line complications.
- Once the incision starts to separate and become infected the entire suture line usually becomes involved.
- Treatment with the McCord System resulted in clearing of the bacteria and complete healing.

## CASE 4 - JW

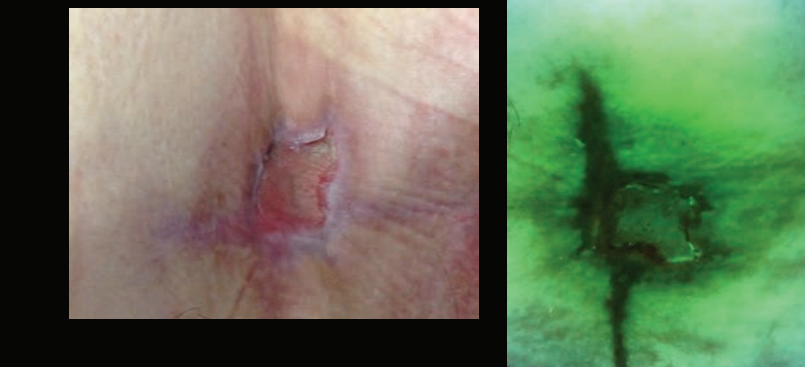
- 61 y/o male s/p revision hip arthroplasty performed at another hospital on 7/09/2023. He developed a post operative surgical site complication managed at the other hospital with Santyl®
- Patient was referred to the wound care clinic at MAMC on 9/07/2023 because of failure to heal for 2 months. On evaluation he had a chronic wound with fibrotic borders and slough in bottom.
- Wound debrided
- Treated from 9/07/2025 – 10/10/2025 with Blastx, Hydrofera Blue Transfer and Mepilex border dressing. Patient changing his dressing every two to three days. Minimal change in size.
- McCord System started on 10/10/2023. Patient instructed on dressing changes at home.
- McCord System from 10/10/2023 – 11/21/2023 with significant improvement in depth and size

### JW – Pre-Treatment



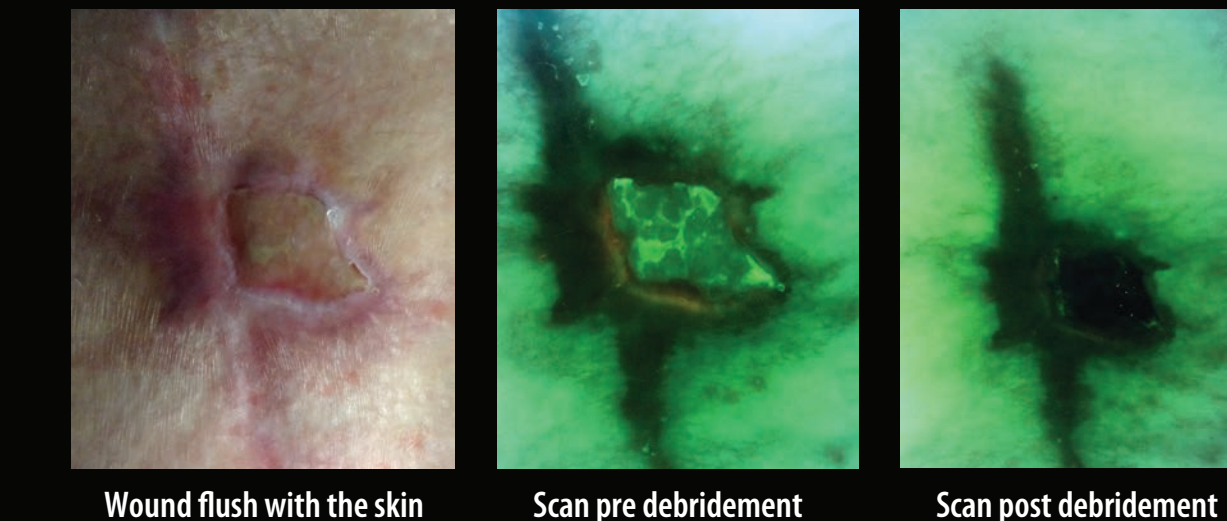
Initial exam had slough in base with a positive bacterial scan. Wound debrided with removal of slough and bacteria. McCord system initiated on 10/10/2023

### JW – 6 Days



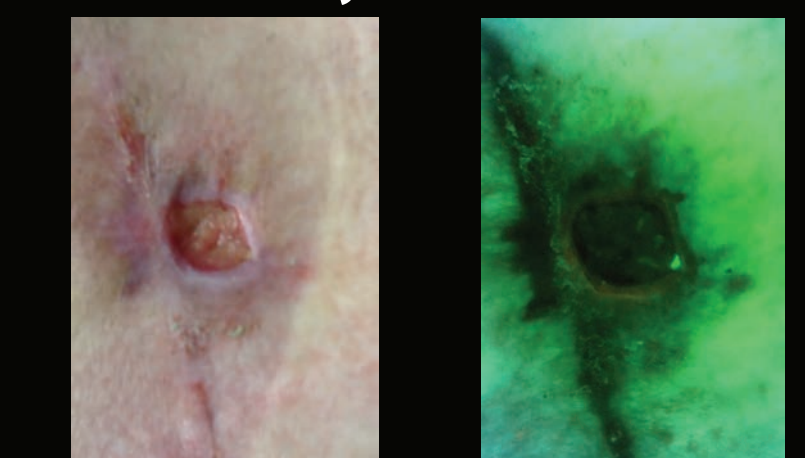
Wound is more superficial with granulation tissue and no bacteria on bacterial scan

### JW – 28 Days



Wound flush with the skin

### JW – 36 Days

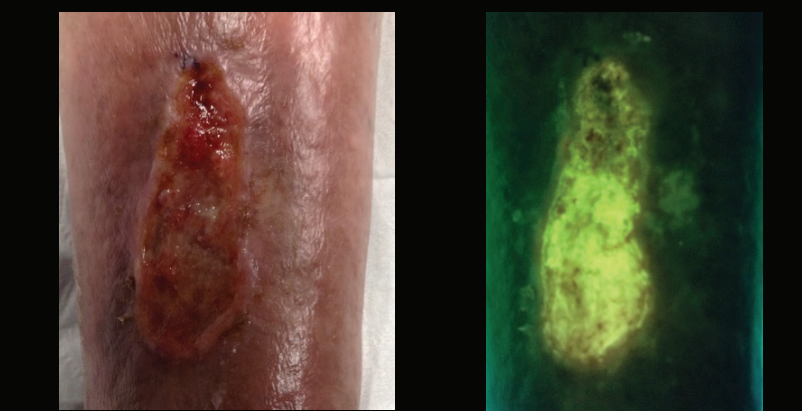


- Patient failed to progress significantly on advanced wound care
- Since initiation of the McCord system the wound has filled in from the bottom and is decreasing in size

## CASE 5 - AF

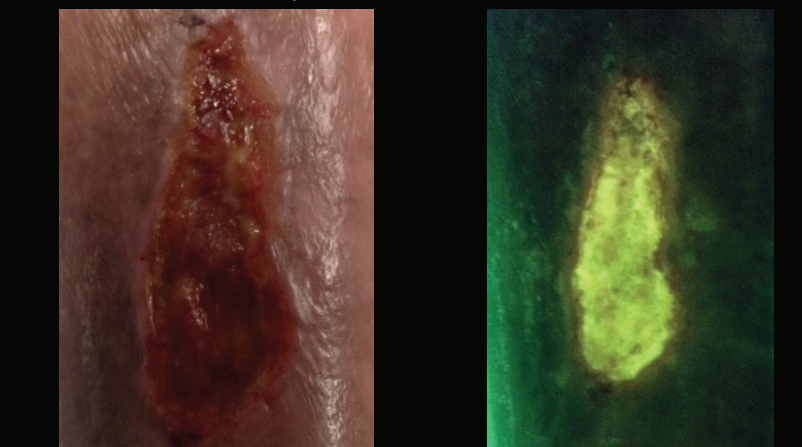
- 58 y/o female with alpha thalassemia
- Left leg ulcer for 22 months – Non-healing wound resulting from a vein harvest for popliteal bypass
- Treated with EO2® with Regranex® for nine months with no significant change in size of the wound
- Started on McCord System on 10/13/2023

### AF – Pre-Treatment



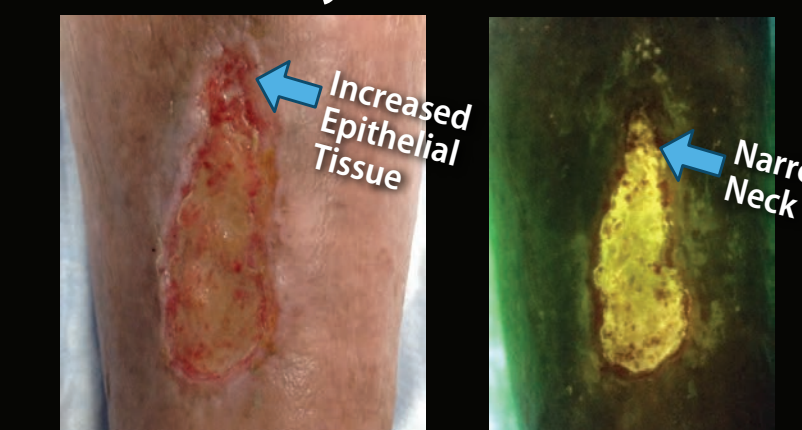Wound cleaned and debrided; continued with Regranex® and EO2® therapy; and added BioRelease® and AgFresh®

### AF – 6 Days



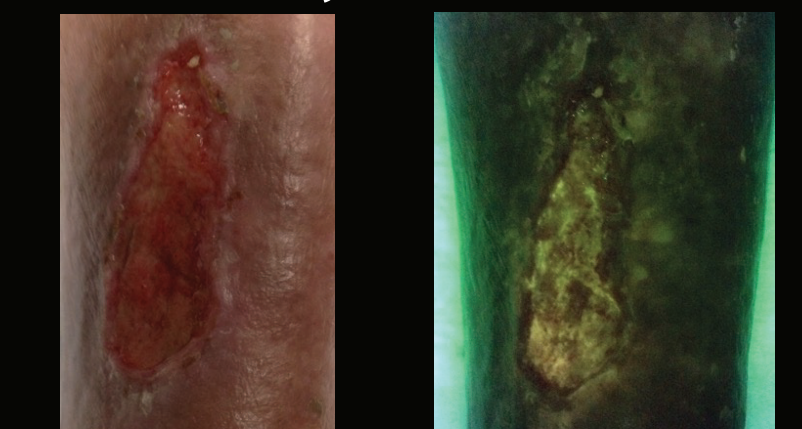
Wound cleaned and debrided. Since initiation of the McCord System, patient has noted an increase in exudate but a significant decrease in pain.

### AF – 12 Days



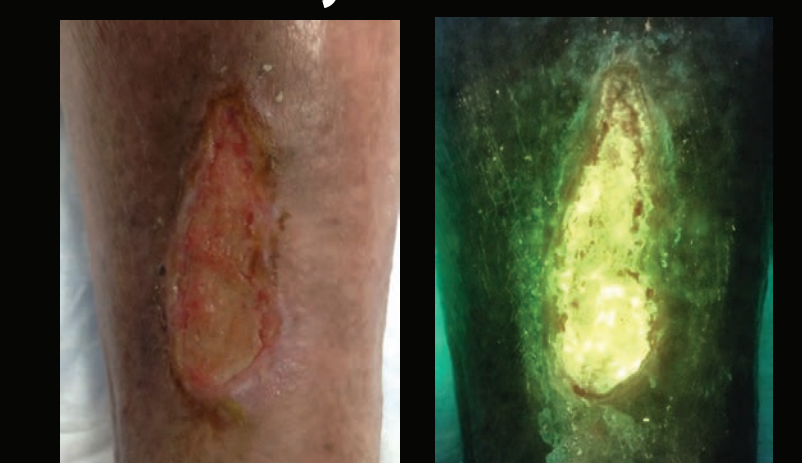Wound cleaned and debrided. Continued with the McCord System. Top of wound is narrower with increased granulation tissue.

### AF – 19 Days



Wound cleaned and debrided; continued Regranex® and EO2®; changed to BioRelease® with no AgFresh®

### AF – 26 Days



Wound cleaned and debrided; continued Regranex®, EO2® and BioRelease®  
Marginal epithelium continues to increase

- Chronic wound present for 22 months that has failed to respond to multiple advanced wound treatments including skin substitutes
- Since initiation of the McCord System in combination with Regranex® and topical oxygen the wound is forming new epithelial tissue

## INVESTIGATOR



**MADIGAN**  
ARMY MEDICAL CENTER

Dr. Charles Andersen; MD, FACS, FSVS, MAPWCA  
Chief, Wound Care Service MAMC  
Clinical Professor; UW, USUHS