

# Application of Dehydrated Amniotic Membrane to Complex Diabetic Foot Ulceration: A Case Study

By: Darnell Blackmon MD, Naomi Lambert BS, Tyler Barrett

## Background

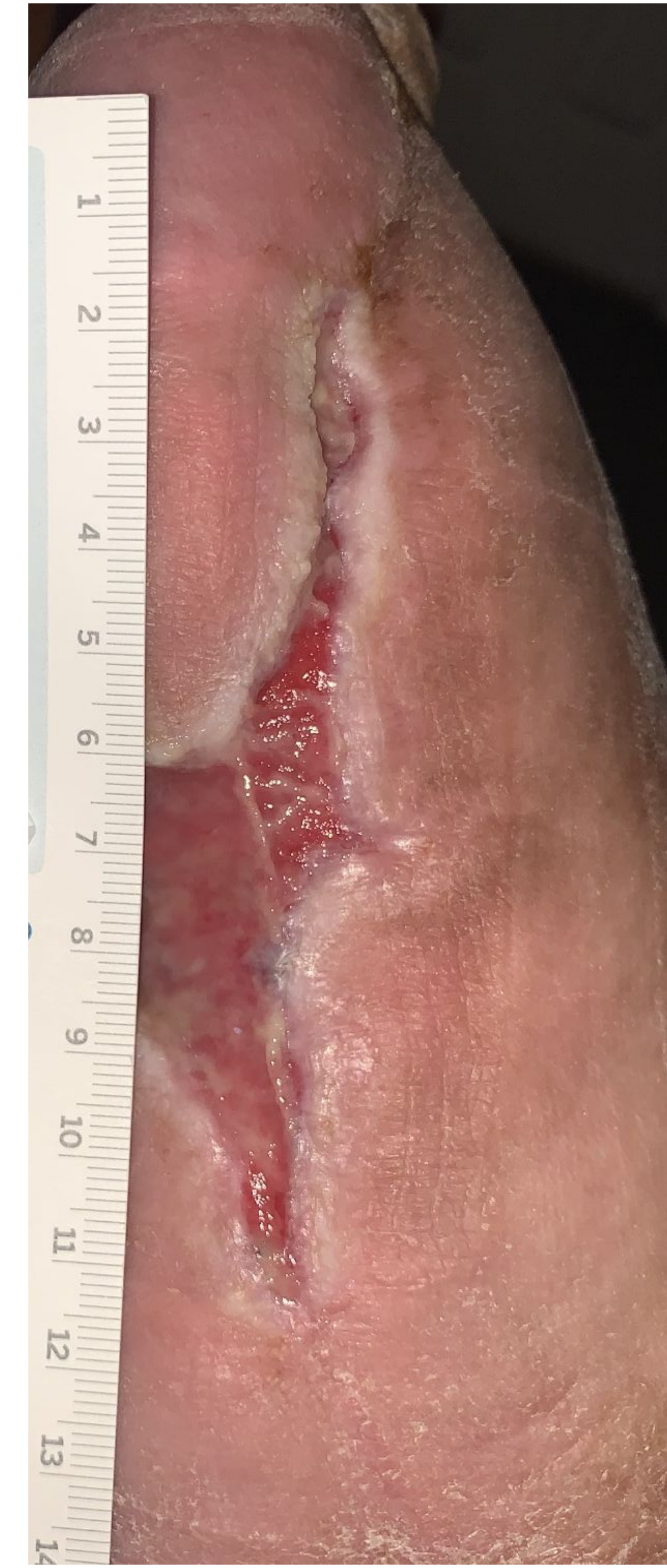Diabetes is an epidemic in the United States and is responsible for millions of deaths yearly worldwide. The chronic disease frequently causes life-threatening ulcers that lead to amputations and much worse. This case study aims to report on the efficacy of Dehydrated Amniotic Membrane Allograft (DAMA) applications to a chronic diabetic foot ulcer complicated by amputation wound. The patient is a 47-year-old male who presented with a medical history of Type 1 diabetes mellitus, kidney failure, congestive heart failure, peripheral arterial disease, venous insufficiency, and hypercholesterolemia. The patient underwent amputation of the right hallux in July of 2022 due to infection from an existing ulcer. A post-surgical wound vac was applied to the incision site but failed to promote closure. The patient began care with Elite Wound Care on November 23, 2022. Upon initial examination, the wound was Wagner grade 2, measuring 10cm x 5cm x 0.4cm with 76-100% slough and 0% epithelialization.

## Methods

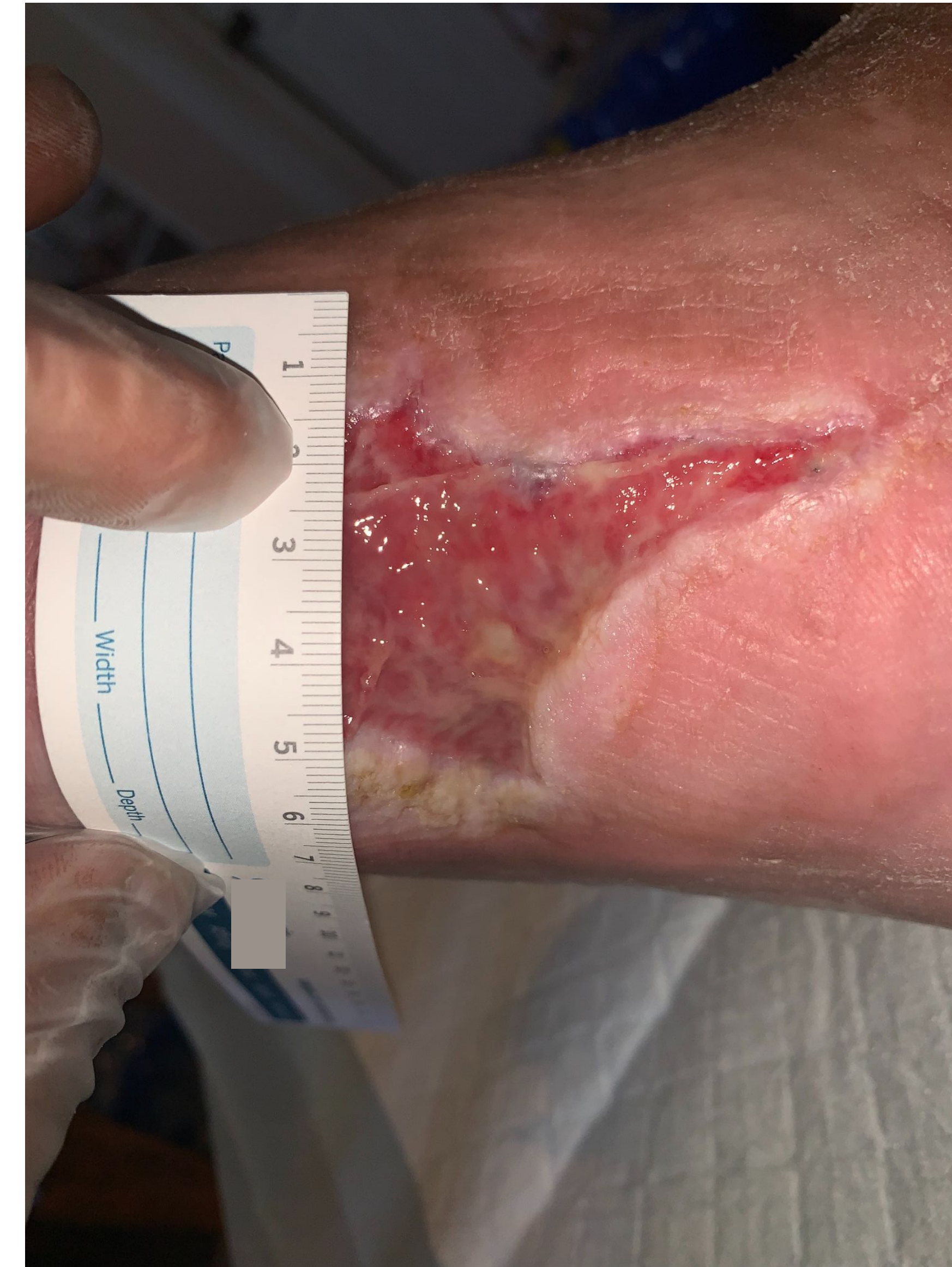The patient received weekly care for 16 weeks to complete the closure, including six weeks of wound prep, followed by ten weekly DAMA applications. Upon the first examination in November, the patient received vascular analysis, debridement, Aquacel, and compression bandaging. The patient was instructed to offload and elevate the foot. The patient then underwent revascularization in December and received the first DAMA patch on 4 January 2023. Over ten weeks, the patient received weekly applications of dual-layer human amniotic membrane allografts (AmnioText) directly on the wound after debridement. The DAMA was secured with 4x4 Adaptic sterile strips and two-layer compression bandaging.

## Results

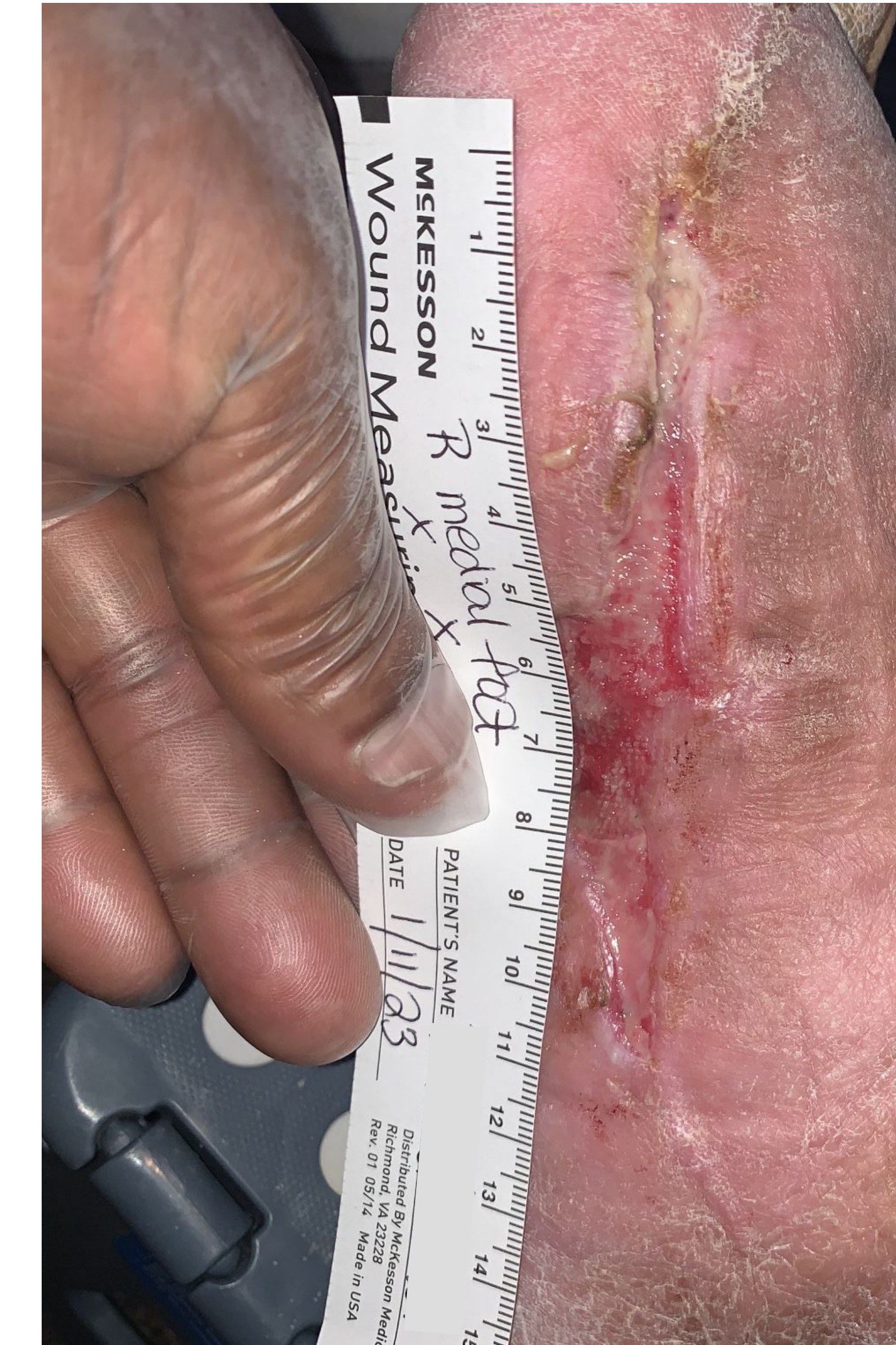As the wound decreased, the applied graft sizes were also reduced. The first graft was 10 cm x 10 cm, and the last was 3 cm x 2 cm. The wound was noted as completely closed, 100% epithelialization, on 15 March 2023, a week after the final DAMA application. The duration of the wound closure was 70 days from the initial allograft application. No adverse events or severe adverse effects from the DAMA application were reported, and there has been no recurrence to date.



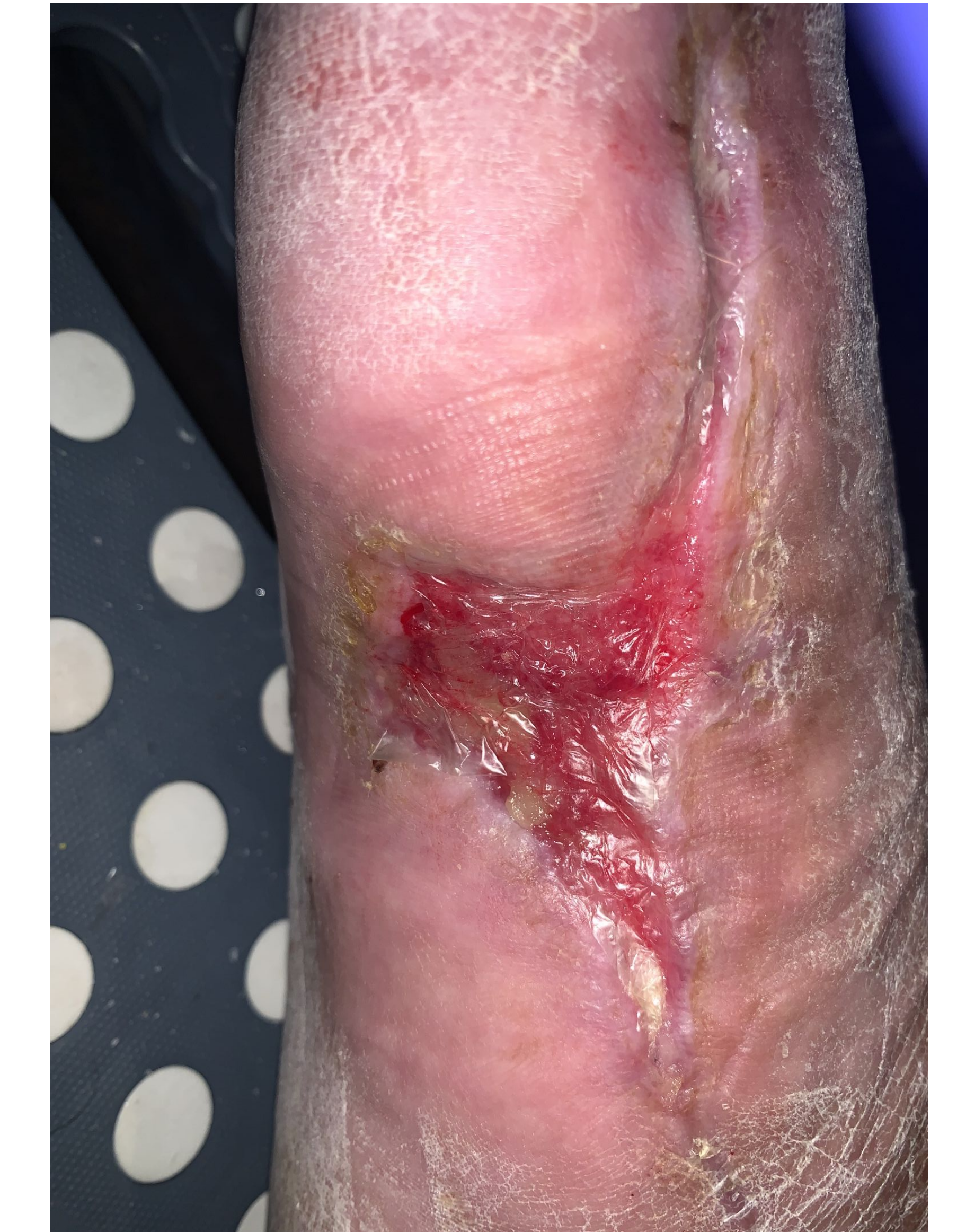01/04/2023



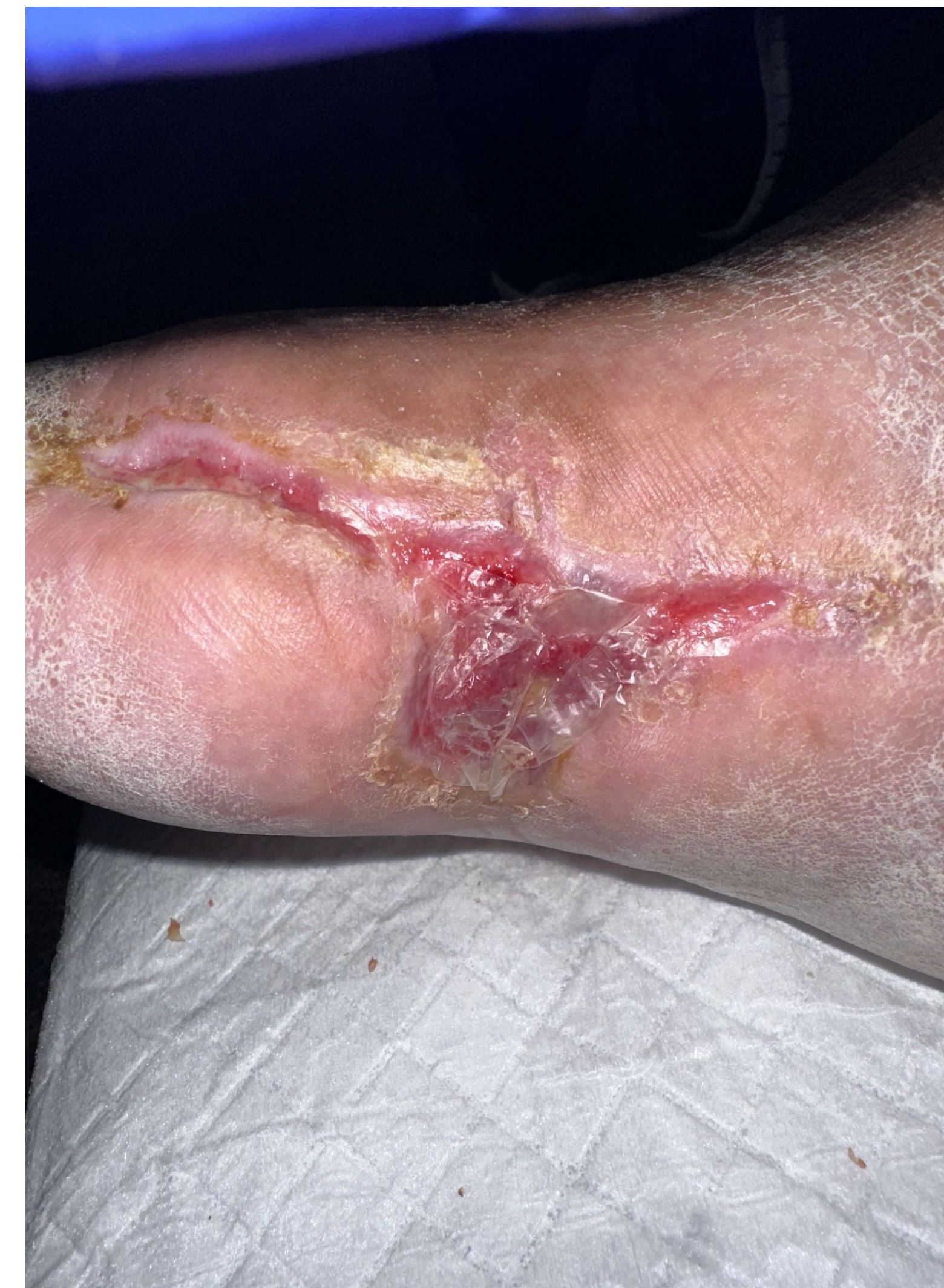01/11/2023



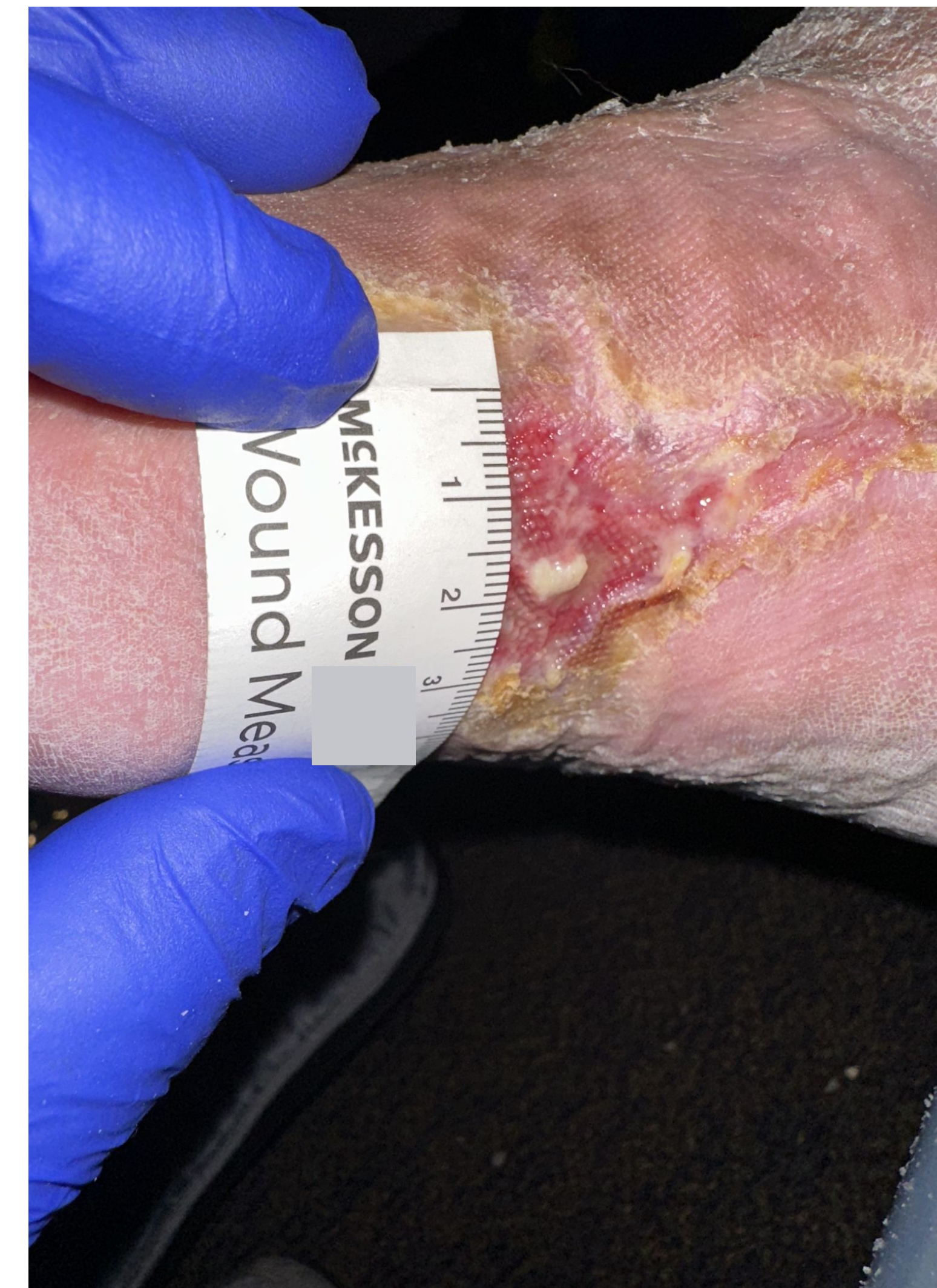01/18/2023



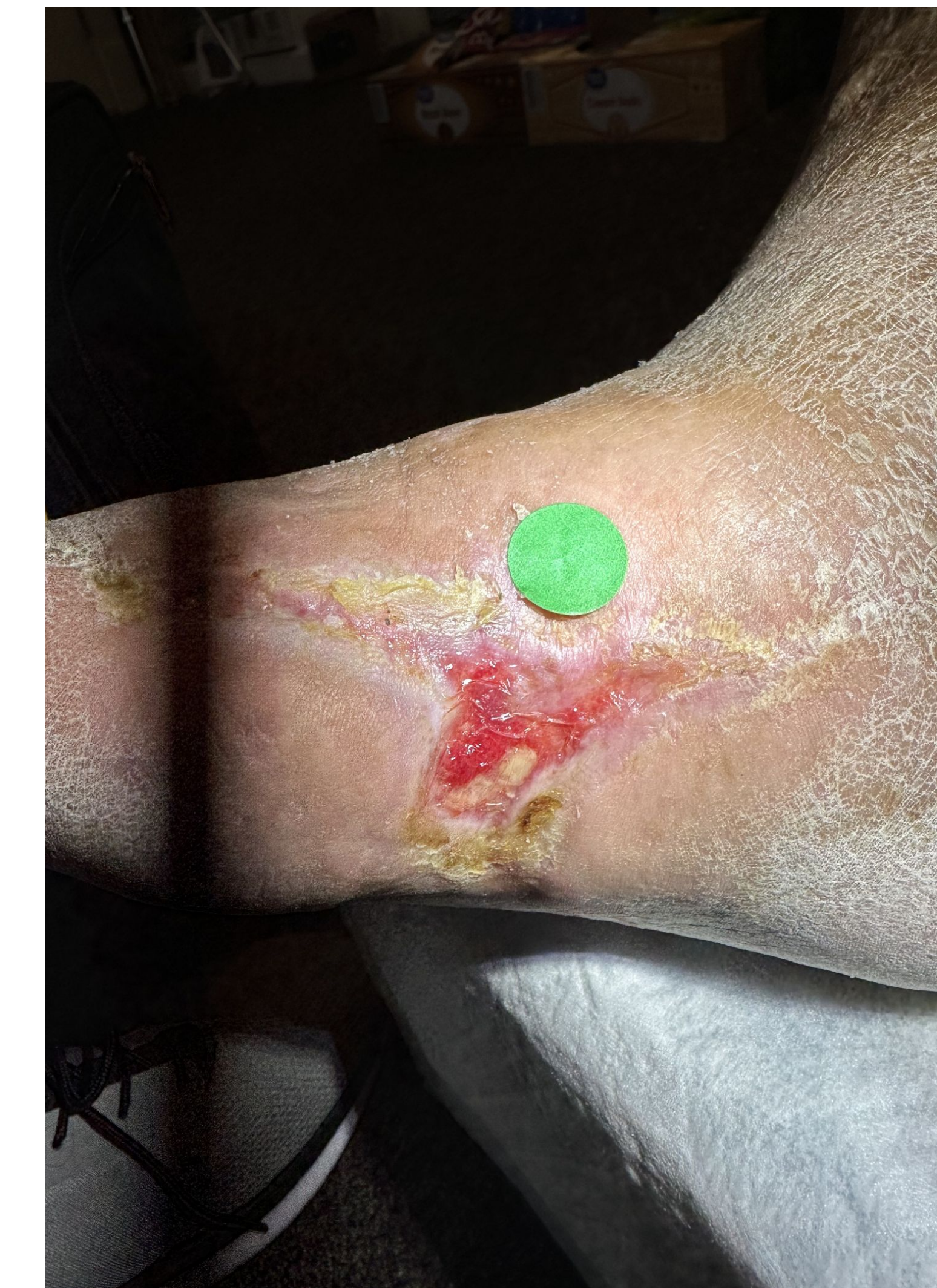01/25/2023



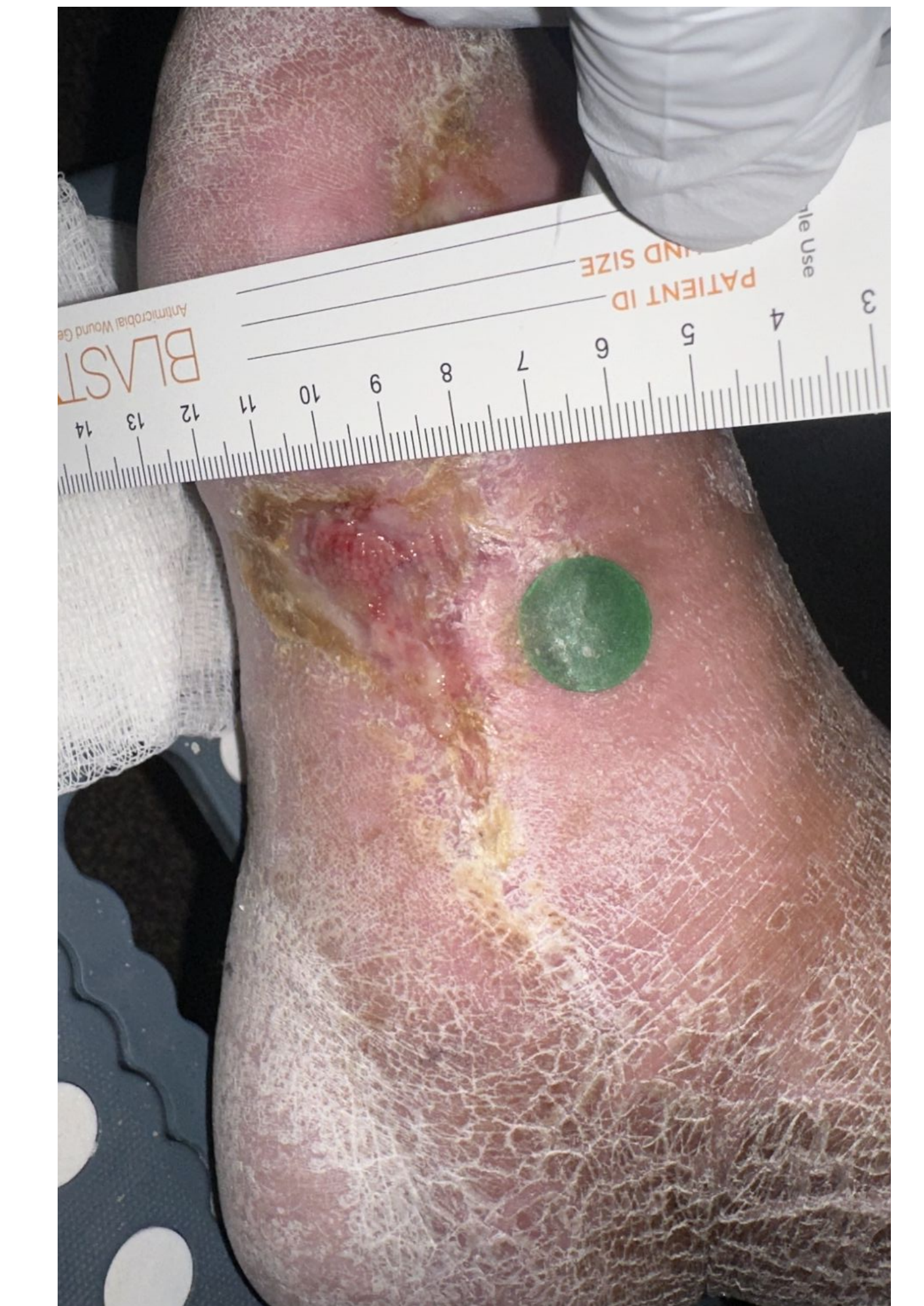02/01/2023



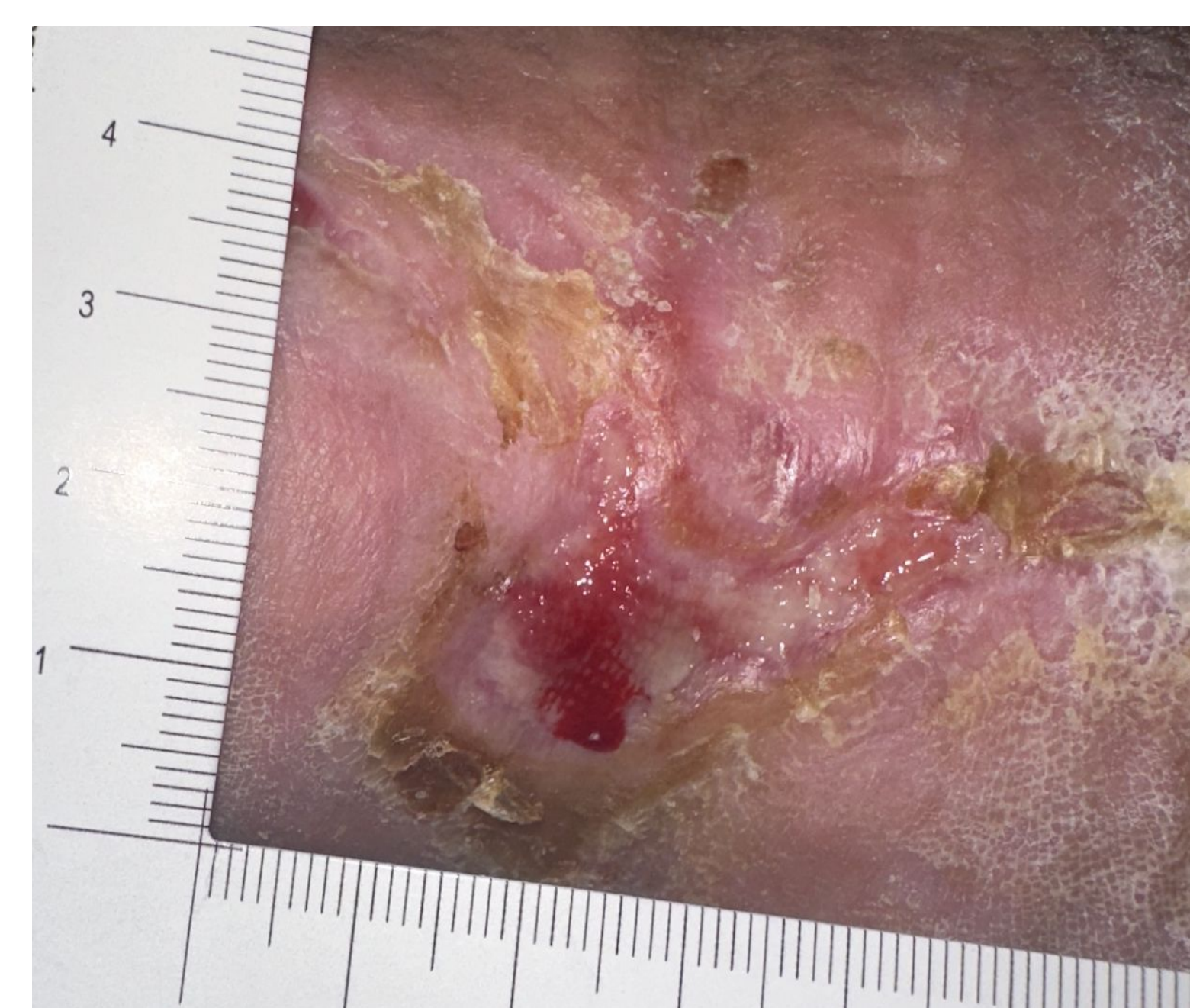
02/08/2023



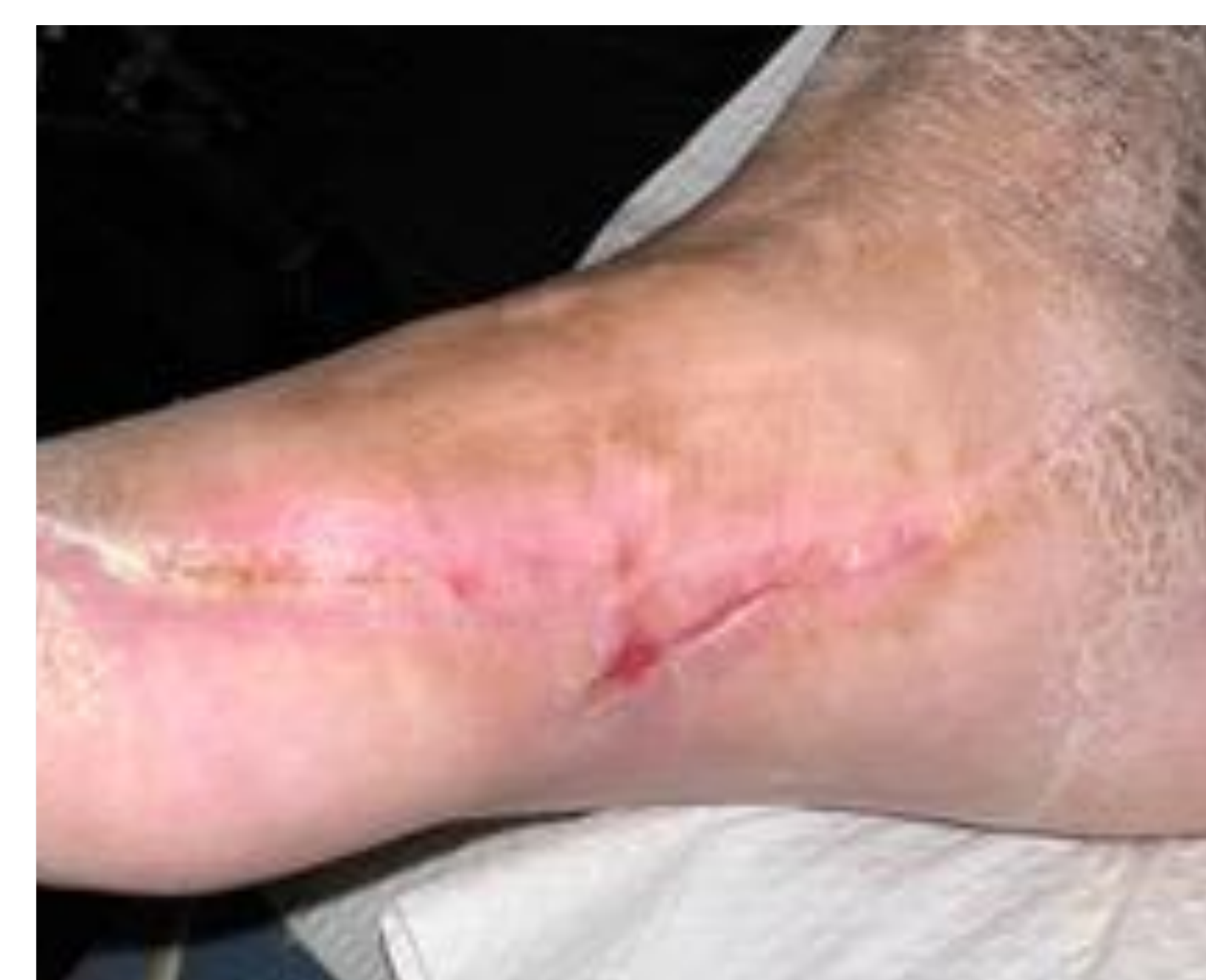02/15/2023



03/01/2023



03/08/2023



4/27/2023

## Conclusion

This case study exhibits that implementing DAMA alongside standard-of-care practices can enhance the body's natural response in closing diabetic-related wounds and avoiding further amputations. The time to wound closure was significantly less than prior interventions as the patient's wound had been open for six months with no progress prior to the DAMA applications. The use of DAMAs preventatively intraoperatively could prevent excessive wound closure time and health care costs. Further studies utilizing randomized controlled trials can provide a more comprehensive evaluation of its effectiveness compared to traditional practices.